TECHNIQUE ARTICLE

Dry Arthroscopy of the Wrist: Surgical Technique

Francisco del Piñal, MD, PhD, Francisco J. García-Bernal, MD, PhD, Daniele Pisani, MD, Javier Regalado, MD, Higinio Ayala, MD, Alexis Studer, MD

From the Instituto de Cirugía Plástica y de la Mano, Private Practice, Hospital Mutua Montañesa, Santander, Spain.

Purpose: To present a method to perform arthroscopic exploration and instrumentation without infusing any fluid.

Methods: The hand is suspended from a bow, with traction on all fingers. Portals are developed as in the classic (wet) wrist arthroscopic procedure except that no water is infused to distend the joint and create the optic cavity. For this procedure the joint must be dried; we use suction through the synoviotomes and neurosurgical patties to accomplish this.

Results: We have performed more than 100 wrist arthroscopies using the dry technique without any undue difficulty.

Conclusions: The dry technique is as effective as the classic procedure, without the cumbersome leakage of water or the risk of compartment syndrome. It allows some sophisticated arthroscopic procedures to be performed that would be impracticable with water. In addition from these benefits, if open surgery is performed after the arthroscopic exploration then the tissue planes are dry, making surgery much easier. The technique is believed to be inappropriate if thermal probes are used. A learning curve exists. (J Hand Surg 2007;32A:119–123.

Key words: Arthroscopy, dry technique, distal radius fracture, wrist diagnosis.

Arthroscopy is now crucial to explore and to treat many wrist conditions. Since the early days of wrist arthroscopy fluid has been considered critical for distending the wrist joint and for maintaining the optic cavity where working.[1,2] Water also is thought to be necessary to debride soft tissues or bone: synoviotomes, suction punch, and burrs all work with water. Infusing water is not without complications, however, and fears of compartment syndrome exist, particularly after fractures.[2–5] To avoid this eventuality, bandaging the forearm, low-pressure pumps, and gravity drainage through a separate outflow have been recommended.[2–5]

Apart from the potential to cause major complications, massive fluid leakage made it impossible to perform intra-articular osteotomies of the distal radius.[6,7] Similarly, vision loss made it impractical to perform some semi-open surgeries, such as a triangular fibrocartilage complex (TFCC) reinsertion at the fovea[8] or a mini-open ulnar styloid resection (unpublished data). A final inconvenience was that the extravasated fluid made any concomitant open surgery awkward.

In other fields of surgery, such as laparoscopy, water is not used to maintain the optic cavity; instead carbon dioxide is used. Levin et al[9] devised a balloon for this purpose when dissecting in soft-tissue planes. Other researchers[10,11] have used traction from the soft tissues to develop the optic cavity when raising flaps. To summarize, water is neither crucial nor necessary to see inside any given cavity. We hypothesized that in the wrist, traction on itself would keep the optic cavity open.

This article presents our initial experience in the technique of what we call *dry arthroscopy* after our

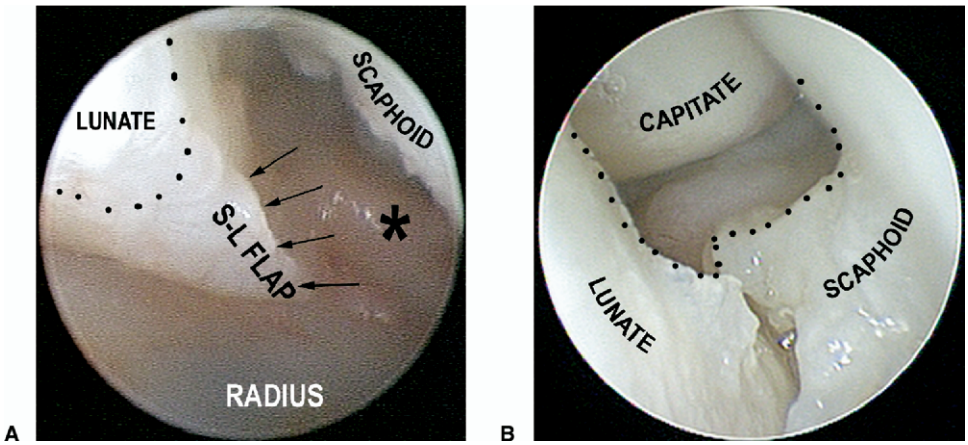

Figure 1. Chronic Geissler grade IV scapholunate ligament tear. The scope is looking from the 3–4 portal of a left wrist (see also Fig. 3, Video 1; this video may be viewed at the Journal's Web site, www.jhandsurg.org). (A) From the radiocarpal joint the complete rupture is evident. There is a clear S-L gap and the membranous portion of the scapholunate ligament has been avulsed from the scaphoid (arrows). On the far center the scapholunate fat pad (Testut ligament) has been marked with an asterisk. (B) Same patient as in panel A. The scope has been advanced through the scapholunate interval to the midcarpal joint, exposing the lunate facet of the scaphoid, the scaphoid facet of the lunate, and the head of the capitate. The distal edges of the corresponding facets of the scaphoid and lunate have been marked with dots.

experience with more than 100 cases. The difficulties encountered and tips to overcome these difficulties are discussed.

Surgical Technique

We perform all of our arthroscopies under tourniquet with the hand placed in traction from a bow[6] with a counterweight of about 5 to 7 kg. A strap holds the arm to the table. Bony landmarks are palpated and transverse incisions are made with a number 15 scalpel blade, with care taken not to go deeper than the dermis. Usually the first portal is the 3–4 and, similar to the rest, it is developed by pushing gently with a straight hemostat. If the surgeon is unsure where the radiocarpal space is located (eg, after a fracture), probing the joint with an intramuscular needle can be helpful. Contrary to the classic wet technique, no water is infused through this needle to distend the cavity before developing the portal.

The scope then is introduced and the joint is explored. In the usual joint there is mucous fluid that does not impede vision. The scope then is brought ulnarly and an ulnar portal (usually the 6-R) is developed. First a needle is introduced to make sure that the surgeon stays distal to the TFC; the portal then is developed.

The remaining steps of joint exploration (radiocarpal, midcarpal, palpation, probing) do not vary from the wet technique (Fig. 1, Video 1; this video may be viewed at the Journal's Web site, www.jhandsurg.org). Synoviotomes and burrs are used similarly; however, the surgeon should remember to keep the side valve of the arthroscope sheath open; otherwise suction will collapse the capsule and obscure the view. The synoviotome, or any other instrument connected to a suction machine, can become clogged because the aspirated debris dries out. If this happens the terminal must be disconnected from the hand piece and cleaned by saline injection. This wastes valuable time. Periodic saline aspiration from an external basin will minimize this.

The dry technique differs from the classic technique in that sometimes the surgeon's vision may not be as clear because blood and debris can stick to the scope's tip. To combat this, we have found the following tips useful.

- Our first recommendation is to avoid getting too close to the scope tip when working with burrs or osteotomes to avoid splashes. It is preferable to first inspect the area of interest and then pull the scope back slightly before inserting the working instruments. For the same reason, the scope tip should not be touched by any instruments.
- If there is a minor splash onto the scope's tip it can be removed by gently rubbing the tip on the local soft tissue (capsule, fat). This will clear the view sufficiently.
- If there is blood or blood clots (eg, after a fracture) the debris can be cleared by injecting 10 to 20 mL of saline through the side valve of the scope and then aspirating with the synoviotome. This should provide a sufficiently dry field.

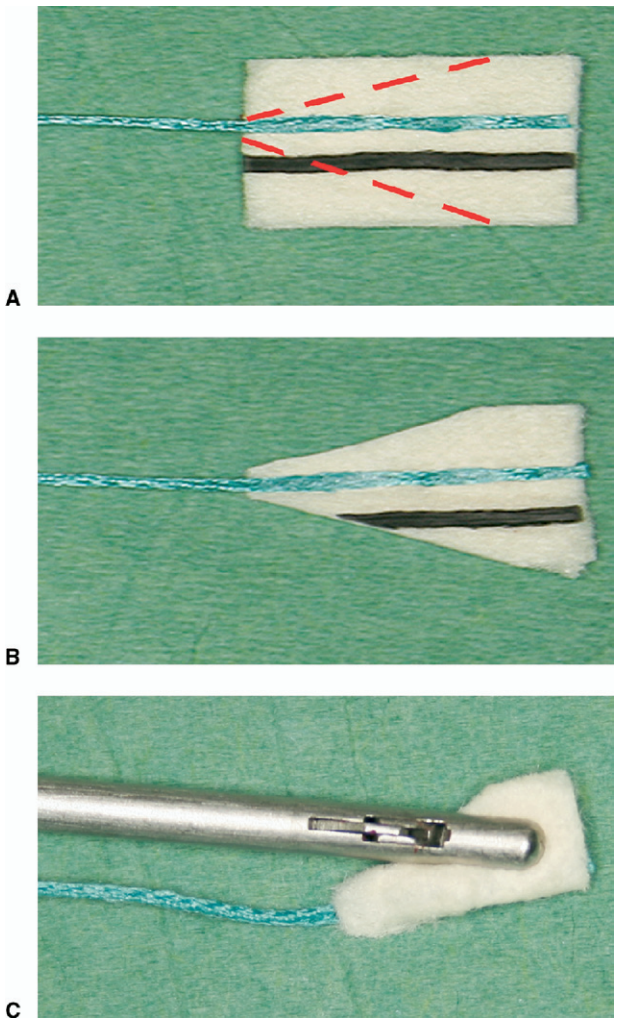

Figure 2. To dry out the surgical field the (A) neurosurgical patties have been modified and the (B) squared tail part has been cut to facilitate its removal. (C) The patty is rolled and introduced into the joint with a grasper. To prevent the patty from entangling or breaking inside the joint the grasper (not the tail) is used to retrieve it. Breakage is not much of a problem because the remaining segment can be retrieved easily with the grasper.

- Sometimes an absolutely dry field is needed. For this we use small (13 × 13 mm) or medium (25 × 25 mm) surgical patties (ref. no. 800-04000, size: ½″ × ½″; model 800-04003, size: 1′ × 1′ [25 × 25 mm]; Neuray; Xomed, Jacksonville, FL). The small patty can be rolled and introduced directly into the joint by a grasper. The large patties have to be modified slightly by cutting them into the shape of a triangle, which facilitates removal from the joint (Fig. 2). If the patties become entangled, they can be removed by pulling on the tail or by retrieval with a grasper.
- If the arthroscopy is performed immediately after elevating the tourniquet then vision can be poor at the beginning but should improve as the surgery proceeds. We realized the vision impairment was caused by condensation at the scope tip as a consequence of the different temperatures (the joint still was warm and the scope was at room temperature). As time goes by the field of vision should improve as the hand cools down. This is easily overcome by immersing the scope tip in warm saline before beginning the surgery.

Discussion

Traditionally wrist arthroscopy has been performed with water in an attempt to maintain the optic cavity; however, as shown in other areas of the body (abdomen, thorax) or when raising flaps,[9–11] water is not required. We have successfully performed more than 100 arthroscopies over the past 2 years. Distal radius fractures, ganglion excision, or ulnar shortening

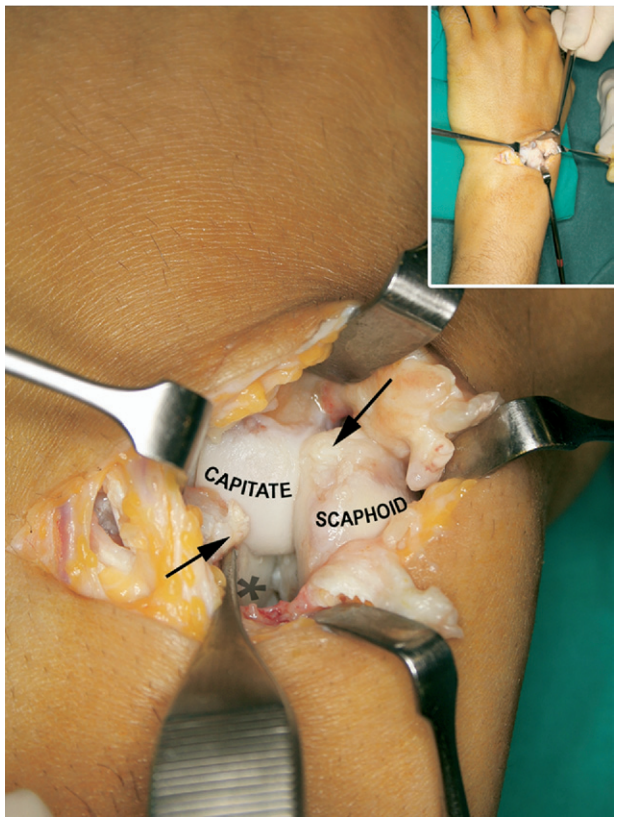

Figure 3. Intraoperative view of a patient who had a diagnostic arthroscopy in which a chronic complete scapholunate ligament tear SL rupture, and an immediate open repair after the Garcia-Elias three-ligament tendonesis (3LT) technique[12] was performed. There is no swelling and the tissue planes are recognized easily. The arrow points to the edges of the chronically ruptured scapholunate (S-L) ligament. *Ulnar facet of the lunate. Inset shows the corresponding panoramic view (same patient as in Fig. 1, Video 1; this video may be viewed at the Journal's Web site, www.jhandsurg.org).

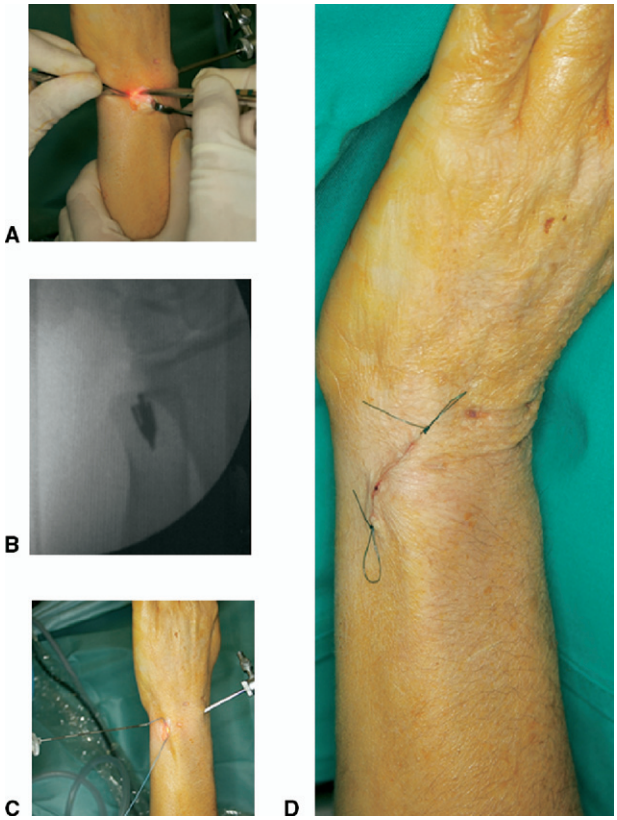

Figure 4. (A) Open resection of the tip of the ulnar styloid after a standard arthroscopic exploration of the radiocarpal and midcarpal joints, (B) debridement of the fovea and introduction of an anchor, and (C) reattachment of the TFCC to the fovea. (D) Swelling at the end of the procedure. Transverse portals usually do not need to be sutured. At the end of the surgery the skin wrinkles at the dorsum of the wrist, attesting to the lack of soft-tissue extravasation.

(Video 2; this video may be viewed at the Journal's Web site, www.jhandsurg.org) can be performed without undue difficulties in relation to the classic technique. Some surgeries, such as reinsertion of the TFCC at the fovea[8] or resection of the ulnar styloid, are performed more easily with the dry technique. Finally, in our experience, intra-articular osteotomies of the distal radius could not be accomplished until after we switched to the dry technique.[6,7]

Water has inherent disadvantages. It runs out through the portals, causing loss of vision, and may cause compartment syndrome.[2–5] The dry technique will prevent the latter from occurring. A major advantage of the dry technique it that an open procedure can be performed concomitantly because the tissues are not infiltrated by water (Fig. 3). Furthermore, we intuitively believe that because there is less swelling at the end of the procedure (Fig. 4), there will be less pain after surgery; however, we have not performed an objective study to support this statement.

Although we do not have any experience, the dry technique is probably inappropriate when using thermal or laser probes. The generated heat cannot dissipate by air alone and, in our opinion, there is a risk of widespread, uncontrollable soft-tissue and/or chondrocyte burning. For this reason we do not advise using this type of device without water running through the area. If the need arises, we do not see any problem in switching from the dry to the classic technique. Once the thermal part of the surgery has been completed the surgeon can switch back again to the dry technique by aspirating any remaining fluid.

The dry technique has a learning curve, not only to overcome the difficulties secondary to vision blurring, but because some signs and findings differ from those found in the wet technique. For example, the inflamed synovium will not float, it will stick to the capsule: its redness and hypertrophy will point to the existence of synovitis. Simi-

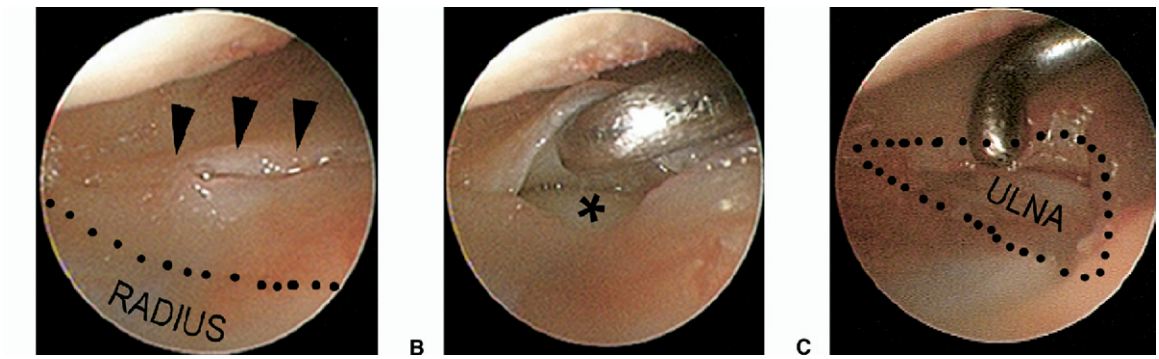

Figure 5. Arthroscopic view of a type I-A TFCC tear with the dry technique. The scope is in the 3–4 portal; the probe is in the 6R portal (right wrist). The junction of the TFC to the radius has been marked with dots. (A) The tear is evident before probing (arrowheads). (B) Probe in 6R portal lifting the flap, exposing the ulnar head (asterisk). (C) After debridement the ulnar dome is visible.

larly, there is no place to perform a "poor man's arthroscopy,"[2] but palpation of the ligaments and the TFC will be the key to diagnosis (Fig. 5).

These differences between the 2 techniques will not impede a surgeon familiar with the classic arthroscopy technique to quickly incorporate the dry technique and benefit from its advantages. As in any change from a familiar technique to a technique that is less familiar, one should be prepared to accept some frustration at the beginning. A giant leap will be made once the surgeon understands that at most times the field of vision will not be completely clear but still will be sufficient to accomplish the goals of the procedure safely. Having a completely clear field of vision except at specific times during the procedure is unnecessary and wastes valuable time.[12]

We thank Robert Jenkins for his help during the English translation of this article. The input of other surgeons (Atzei and Luchetti from Italy, Zaidemberg and Perroto from Argentina among others) on the inception of the dry technique is also recognized.

Received for publication July 12, 2006; accepted in revised form October 23, 2006.

Dr Pisani was supported by a grant from the University of Milan and Multimedica Hospital (Prof. G. Pajardi), Milan, Italy (to D.P.).

No benefits in any form have been received or will be received from a commercial party related directly or indirectly to the subject of this article.

Corresponding author: Francisco del Piñal, MD, PhD, Calderón de la Barca 16-entlo, E-39002-Santander, Spain; e-mail: drpinal@drpinal.com or pacopinal@ono.com.

0363-5023/07/32A01-0015$32.00/0
doi:10.1016/j.jhsa.2006.10.012

References

1. Botte MJ, Cooney WP, Linscheid RL. Arthroscopy of the wrist: anatomy and technique. J Hand Surg 1989;14A:313–316.
2. Geissler WB, Freeland AE, Weiss A-PC, Chow JCY. Techniques of wrist arthroscopy. J Bone Joint Surg 1999;81A: 1184–1197.
3. Geissler WB. Arthroscopically assisted reduction of intra-articular fractures of the distal radius. Hand Clin 1995;11:19–29.
4. Doi K, Hattori Y, Otsuka K, Abe Y, Yamamoto H. Intra-articular fractures of the distal aspect of the radius: arthroscopically assisted reduction compared with open reduction and internal fixation. J Bone Joint Surg 1999;81A:1093–1110.
5. Geissler WB. Intra-articular distal radius fractures: the role of arthroscopy? Hand Clin 2005;21:407–416.
6. del Piñal F, Garcia-Bernal FJ, Delgado J, Sanmartín M, Regalado J. Correction of malunited intra-articular distal radius fractures with an inside-out osteotomy technique. J Hand Surg 2006;31A;1075–1082.
7. del Piñal F. Correction of malunited intra-articular distal radius fractures with an inside-out osteotomy technique. In: Slutsky D, ed. Wrist and hand arthroscopy—a practical approach. Philadelphia: Elsevier 2007 (in press).
8. Atzei A, Luchetti R, Carita E, Papini-Zorli I, Cugola L. Arthroscopically assisted foveal reinsertion of the peripheral avulsions of the TFCC. J Hand Surg 2005;30B:40.
9. Levin LS, Rehnke R, Eubanks S. Endoscopic surgery of the upper extremity. Hand Clin 1995;11:59–70.
10. Friedlander L, Sundin J. Minimally invasive harvesting of the latissimus dorsi. Plast Reconstr Surg 1994;94:881–884.
11. Venkataramakrishnan V, Southern SJ. Endoscopic rectus harvest: a simplified sheath-saving technique. Ann Plast Surg 1997;39:573–577.
12. Garcia-Elias M, Lluch AL, Stanley JK. Three-ligament tenodesis for the treatment of scapholunate dissociation: indications and surgical technique. J Hand Surg 2006;31A: 125–134.