

Vascularized Bone Blocks From the Toe Phalanx to Solve Complex Intercalated Defects in the Fingers

Francisco del Piñal, MD, PhD, Francisco J. García-Bernal, MD, PhD,
Julio Delgado, MD, PhD, Marcos Sanmartín, MD, Javier Regalado, MD,
Leopoldo Cagigal, MD

From the Instituto de Cirugía Plástica y de la Mano, Hospital Mutua Montañesa, and Clínica Mompía, Santander, Spain.

Purpose: Vascularized bone transplants resist infection and allow rapid healing but keeping small bony segments vascularized, as needed for a finger defect, is a challenge. The purpose of this article is to present a cohort of patients with traumatic intercalated compound bony defects in the fingers that were reconstructed by a vascularized toe phalanx (or part of a phalanx) in a single stage.

Methods: Eight patients were treated with an intercalary vascularized bone graft that included a part of the proximal phalanx (3 patients), most of the middle phalanx (4 patients), or a portion of each phalanx (1 patient) of a second toe (totaling 9 bone blocks). There was an associated soft-tissue defect in each patient, an infection in 6 patients, and cartilage loss in 4 patients. The toes were pedicled on the proper digital artery (6 patients) or a segment of the first dorsal metatarsal artery (2 patients). A mean length of 12 mm of vascularized bone was transferred. The associated skin island varied from a minimum of 2 × 1 cm to a maximum of 5 × 3 cm. Bleeding from all of the bone surfaces was evidenced once the clamps were released. The homolateral digital nerve and the contralateral neurovascular pedicle of the toe were kept in place. The toe defect was treated by soft-tissue arthroplasty or arthrodesis. No toe was amputated.

Results: Radiologic bony union was evident at 4 to 6 weeks, except in 1 patient with an acute infection whose distal union failed to unite at 6 weeks because the infection recurred. Finger length loss averaged 3 mm. All patients returned to their preoperative occupation.

Conclusions: In this group of patients the toe phalanx reliably maintained its vascularization, allowing us to solve compound osteocutaneous defects in the fingers in a single stage. Donor site morbidity was minimal. (J Hand Surg 2006;31A:1075–1082. Copyright © 2006 by the American Society for Surgery of the Hand.)

Type of study/level of evidence: Therapeutic, Level IV.

Key words: Bone defect, microsurgery, toe-to-hand transfer, compound loss, vascularized bone graft.

Reconstruction of intercalated bony defects of the fingers is challenging. Most cases can be solved by means of nonvascularized bone grafts, either corticocancellous^{1,2} or spongiosa.^{3–5} However, under certain circumstances,^{6–10} a vascularized bone graft may be a better option. Long bone defects, or smaller defects associated to a soft tissue defect, infection, a poor scarred bed, or when a piece of cartilage needs to be included are among some of them.

There are several reliable free vascularized bone graft donor sites when a large defect needs to be reconstructed^{11–13} but very few when a small block of bone is needed.^{14,15} This is partly because the smaller the bone graft to be harvested the more difficult it is to include its feeding vessels. In addition in some cases the intercalated defect in the fingers has a concomitant soft-tissue defect, limiting the possible donor sites even further. The most popular alternative

Table 1. Demographics and Surgical Details

Patient	Age, y	Affected Finger	Recipient Site Location	Main Problem	Skin Defect	Other	Days Since Trauma
1	21	Middle	DIP	Chronic infection	Yes	—	180
2	20	Index	DIP	Chronic infection	Yes	—	65
3	53	Index	Base of P1	Infection/cartilage defect	Yes	FDS/FDP injury	7
4	19	Index	DIP	Infection, necrosis	Yes	—	14
5	24	Index	Hemicondyle/defect P1	Osteochondral defect	Yes	P2 malunion	60
6	36	Index	P2 shaft/partial base	Infection, necrosis	Yes	Cartilage defect	15
7	34	Small	Hemicondyle P1/ hemibase P2	Osteochondral defect	Scar	None	103
8	57	Ring	DIP-P3	Chronic infection	Yes	None	39

FDP, flexor digitorum profundus; FDS, flexor digitorum superficialis; P1, proximal phalanx; P2, middle phalanx; P3, distal phalanx.

for this scenario is to combine a nonvascularized bone graft with a local or free flap for coverage.^{1,2,16,17}

The purpose of this study was to present a group of patients with intercalated compound osteocutaneous defects of the fingers that were reconstructed with a vascularized toe phalanx (or part of a phalanx) in a single stage. In this article we describe this group and the surgical details and assess the results.

Materials and Methods

Over a 3-year period 9 small bone blocks were harvested from the toe phalanx and transplanted to 8 fingers. (One finger received 2 blocks). The defects were located as follows: 1 at the base of the proximal phalanx, 1 at the distal aspect of the proximal phalanx, 1 at the proximal interphalangeal (PIP) joint, 1 at the middle phalanx, and 4 at the distal interphalangeal (DIP) joint.

All patients were healthy manual workers (mean age, 33 y; range, 19–57 y). Patients 4 and 8 were smokers (1 pack/d). All fingers had some type of concomitant soft-tissue defect and required the inclusion of a skin island. Three fingers had an acute infection after a failed reconstruction attempt with local tissues (patients 3, 4) or a failed intercalated ectopic replantation (patient 6). Three fingers (patients 1, 2, 8) had a chronic bony infection with a sinus tract. In an attempt to eradicate the infection an average of 3 procedures had been performed previously, including 1 performed by us on patient 1. Four fingers had a concomitant cartilage defect that was reconstructed by a vascularized osteochondral graft (patients 3, 5, 6, 7). All were work-related injuries covered by workers' compensation.

The fingers had pulp sensibility preserved on both sides (5 patients) or at least on the radial side of the index finger (3 patients). Amputation was offered as an alternative to all distal defects but was rejected by the patients and family (patients 1, 2, 4, 6, 8). Arth-

rodesis with slight shortening also was offered to 4 of the patients who had an osteochondral defect (patients 3, 5, 7) (Table 1).

In 4 patients with infection around the DIP joint the bone block was used to maintain finger length after the radical debridement and to bring well-vascularized tissue to span the gap (patients 1, 2, 4, 8). In 2 acutely injured patients (patients 3, 6) the vascularized bone graft was used to solve a compound bone and soft-tissue defect. In addition those 2 patients suffered a concomitant loss of bone and cartilage on the neighboring joint (metacarpophalangeal joint in 1 patient and PIP joint in the other), which was reconstructed by including a portion of cartilage with the toe phalanx as a vascularized osteochondral graft.¹⁰ Finally patients 5 and 7 had an osteochondral defect involving the PIP joint with soft-tissue loss that had healed by secondary intention. A matching piece of vascularized osteochondral graft was harvested from the toe phalanx together with a skin island for solving the joint-soft-tissue defect. Before surgery and at the last visit the active range of motion (AROM) was measured in the involved joints with a goniometer. Preoperative motion, however, could be measured only in the PIP joints of patients 5 and 7 (20° and 0°, respectively). Patients 3 and 6 had negligible AROM because of severe pain caused by either infected joints or concomitant open wounds, which impeded cooperation.

Taking into consideration the recipient site requirements—that is, the bone, soft tissues and/or cartilage, and vessels available—the appropriate phalanx was selected (Fig. 1A). Before surgery the presence of a Doppler signal on the toe's digital artery was ascertained. No other vascular study was performed. Smokers were advised to quit for at least 4 weeks after surgery.

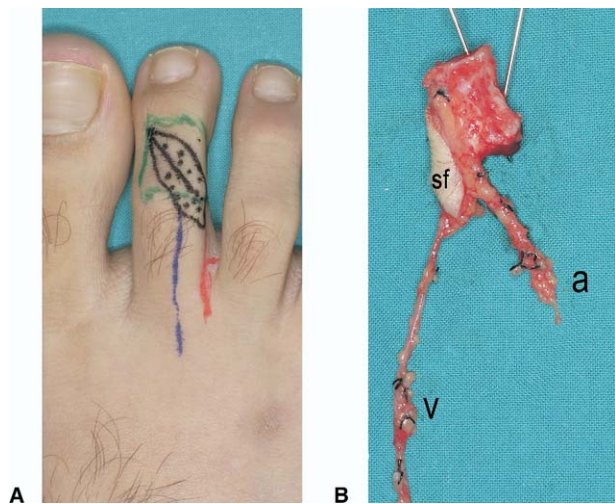


Figure 1. (A) Design of the flap: middle phalanx osteocutaneous flap (patient 1). (B) The middle phalanx of the second toe after being raised and viewed from its plantar-lateral aspect. The digital nerve is preserved on the donor site. A, lateral plantar digital artery of the second toe; v, subcutaneous vein; sf, skin flap.

Flap Harvesting

In principle the procedure is similar to a standard toe harvesting with some particularities highlighted as follows. A subcutaneous vein first is dissected and isolated through a dorsal zigzag incision. The skin flap is incised on the plantar side (the side of the pedicle). The plantar toe skin is reflected plantarward including the digital nerve, which is separated from the artery and left intact on the toe. Great care is taken to keep the connections intact between the digital artery, bone, skin, and vein dorsally by including a soft-tissue cuff over the bone. The digital artery then is dissected proximally and side branches are tied off with 5-0 silk, clips, or 9-0 nylon depending on their size. Traction on these tiny branches is to be avoided because avulsion from the main digital artery may cause persistent spasm or even failure of the part to revascularize.¹⁸ The digital artery is ligated distally to the bone to be harvested.

Once the dissection on the pedicle side is terminated the contralateral side is dissected out rapidly by incising the skin island and performing a subperiosteal dissection of the phalanx. The extensor tendon can be left on the foot or harvested if needed in the finger. The neurovascular pedicle, which maintains the donor toe viability, does not need to be seen. Only nutrient branches to the bone from this pedicle need to be ligated carefully, again avoiding avulsion because this may endanger the toe's blood supply. The flexor sheath is open and the flexor tendons are reflected plantarward. Care should be taken not to

avulse the vincular tissue because this may damage the tiny rete of vessels located at the plantar aspect of the phalanx. The segment of bone to be harvested then is cut with an oscillating saw and the tourniquet is released. We try to cut the exact amount of bone needed before disconnecting the phalanx from the toe because afterward it is very difficult to manipulate the small block of bone. The flap then is ready to be transferred and revascularized in the usual way (Fig. 1B).

A mean of 12 mm of bone was harvested (range, 6–19 mm). The skin island varied from a minimum of 2×1 cm to a maximum of 5×3 cm. The donor vessel was the proper digital artery in 6 patients and the first dorsal metatarsal artery in 2 patients. Bleeding from all of the surfaces was evident once the tourniquet was released. Flap harvesting took from 70 minutes to 105 minutes. The bone was fixed with crossed 1.0-mm K-wires except in cases of joint reconstruction, for which we preferred 1.5-mm compressive screws. Revascularization was performed end-to-end to a digital artery in all patients. Venous drainage was accomplished by anastomosing a dorsal vein end-to-end to a subcutaneous vein in the digital web. In most patients continuous 10-0 nylon (on a 100- μ m needle) was used for the arteries and continuous 9-0 nylon (on a 150- μ m needle) for the veins. The bone bled again and the skin flaps showed good capillary refill once the clamps were released. Transitory spasm is quite common when dealing with very small vessels—toe digital arteries are in the range of 0.6 to 1.2 mm; the veins range from 1.0 to 2.0 mm—and if present it was reverted by using topical verapamil. In addition, just before clamp release a bolus of 1,000 U of heparin was injected intravenously. Thereafter a continuous perfusion of dextran 40 and heparin (25 mL of dextran 40/250 U of heparin/h) was given for the first 4 days and reduced to 12 mL of dextran 40/120 U heparin per hour for a further day. Patients were discharged on day 6 receiving low-molecular-weight heparin for an average of 2 weeks or less depending on ambulation. The flaps were monitored by assessing the capillary refill, color, and Doppler probe results hourly for 48 hours, decreasing to every 2 and then to every 4 hours afterward. No vascular crisis occurred (Fig. 2).

In 1 patient a rotation flap from the dorsum of the large toe was used to close the defect on the toe (patient 6). All other donor sites were closed primarily as a result of bone shortening and local tissue tailoring. The space left by the bone harvested was closed partially by axial collapse and by suturing the extensor to the flexor tendons similar to that recommended for children by Buck-Gramcko.¹⁹ Toes were

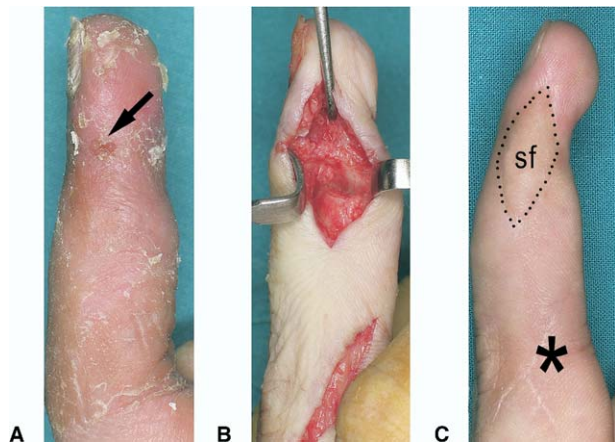


Figure 2. Patient 1. (A) Preoperative condition after 3 previous procedures including 2 attempts of arthrodesis (1 with bone graft). The initial injury was open fracture dislocation of the DIP joint. Arrow points to a draining sinus. (B) Radical debridement of the granulating, scarred soft-tissue and infected bone. (C) Two years after surgery with no signs of recurrent infection. The location of the arterial anastomosis has been marked with an asterisk. sf, skin flap.

stabilized temporarily by 1 or 2 longitudinal K-wires for 4 to 6 weeks. In patients 5 and 7 the proximal and middle phalanges were fused.

Union was assessed clinically and radiographically at regular intervals. Clinical bony union was thought to have occurred once there was no pain on palpation or mobility on manual stress. Radiologic union was defined as occurring when trabeculae crossed the bony junction. Finger length was studied by measuring the reconstructed and contralateral healthy sides with a ruler on plain x-rays. Comparison with preoperative x-rays was misleading because the bone ends required intraoperative debridement; therefore this comparison is not included. An indirect estimation of the bony defect can be inferred by considering the bone block size. At a minimum follow-up period of 6 months (average, 17 mo, range, 6–33 mo) patients were asked about any foot complaints. They also were asked to assess the cosmetic aspect of the donor site with a visual analog scale (range: 0, very ugly to 10, normal). In addition they were asked about whether they would recommend the procedure to others. To evaluate the morbidity of the donor site the American Orthopaedic Foot and Ankle Society questionnaire for lesser toes also was provided.²⁰

Results

Results are summarized in Table 2.

Patients remained hospitalized an average of 6 days after the surgery (range, 5–7 d). Patient 6 was

Table 2. Surgical Details and Results

Patient	Donor Site Location	Bone Size, mm	Skin Flap Size, cm	Artery Donor ⇒ Recipient	Hospitalization	Finger Length, mm (Aff/Contra)	AROM at Involved Joint, °	RTW, d	Donor Site Complications	Foot Appearance, VAS score	AOFAS ²⁰ Score*
1	P2	13	2 × 1	LPDA ⇒ radial DA	6	92/93	DIP ⇒ fused	43	None	9.0	95
2	Base P1	13	2.5 × 1	FDMA ⇒ radial DA	6	85/90	DIP ⇒ fused	63	None	9.0	85
3	Base P1	13	2 × 1	FDMA ⇒ ulnar DA	7	67/70	MCP ⇒ 0–75	112	Transient metatarsalgia	9.5	95
4	P2	10	3.5 × 2	MPDA ⇒ ulnar DA	5	75/80	DIP ⇒ fused	67	None	8.0	95
5	Head P1	12	2.5 × 1.0	MPDA ⇒ ulnar DA	6	89/89	PIP ⇒ 10–80	75	None	9.5	95
6	Base–shaft P1	19	5.0 × 2.5	MPDA ⇒ ulnar DA	6 + 28	79/88	PIP ⇒ 0–65	180	None	8.0	85
7†	Hemicondyle P1/hemibase P2	11/6	2.5 × 1	MPDA ⇒ radial DA	5	62/62	PIP ⇒ 30–90	120	None	9.0	95
8	P2	13	2.0 × 1.5	MPDA ⇒ ulnar DA	6	89/91	DIP ⇒ fused	90	None	9.0	95

Aff, affected; AOFAS, American Orthopaedic Foot and Ankle Society questionnaire; Contra, contralateral; DA, digital artery; FDMA, first dorsal metatarsal artery; LPDA, lateral plantar digital artery; MCP, metacarpophalangeal; MPDA, medial plantar digital artery; P1, proximal phalanx; P2, middle phalanx; RTW, return to work; VAS, visual analog scale.
 *Maximum score was 95 points because in every patient motion at the interphalangeal joint was considered absent.
 †This patient had 2 bony segments taken from the proximal and middle phalanges of a toe to reconstruct a hemijoint defect on the PIP joint.

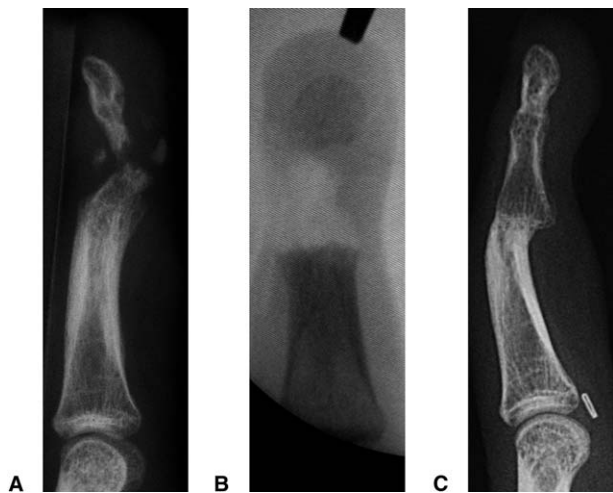


Figure 3. Destruction of the DIP joint and most of the distal phalanx in a case of chronic infection (patient 1). The PIP joint, at the bottom of the picture, is normal. (A) Preoperative x-ray. (B) Radial debridement: intraoperative fluoroscopy image. (C) Lateral x-ray taken 2 years after surgery.

readmitted to the hospital for a stay of 28 days for treatment of a recurrent infection (discussed later).

In all patients clinical bone union occurred earlier than 4 weeks except in patient 6, in whom infection recurred. Radiologic healing was more difficult to assess, particularly when rigid fixation (screws) was used, but it was evident at 5 weeks in all patients (Fig. 3) except patient 6. In patient 6, who had an acute infection, infection recurred 6 weeks after the

surgery in the distal graft–distal phalanx interface. The infection was controlled by a new debridement, cancellous bone grafting, and a 4-week course of intravenous antibiotics. Radiologic union occurred 6 weeks after the second surgery. No infection had recurred at the latest follow-up evaluation. Finger length was restored to an average of within 3 mm of the contralateral finger (range, 5–0 mm) (Fig. 4) except in patient 6, in whom a bone loss of 9 mm occurred after the secondary debridement.

The results of the AROM of the 4 joints reconstructed with a vascularized osteochondral graft (patients 3, 5, 6, 7) are reported in Table 2. Comparison with preoperative values could be made only in patients 5 and 7, who had 20° and 0° of motion, respectively, in the involved PIP joint. The other 2 reconstructed patients had negligible but unmeasured AROM before surgery.

All 4 DIP joints fused successfully.

No specific problems were detected in the foot (Table 2). Patients were allowed to walk in a postoperative stiff-soled shoe after 2 to 3 days. K-wires were removed at about 5 to 6 weeks. Patient 3 complained of metatarsalgia at 2 months. This initially went unappreciated and responded to a short course of rehabilitation and shoe insoles at 3 months. At the latest visit (20 mo) this patient was working full time without any pain or limitation despite the fact that most of his work required standing. No other

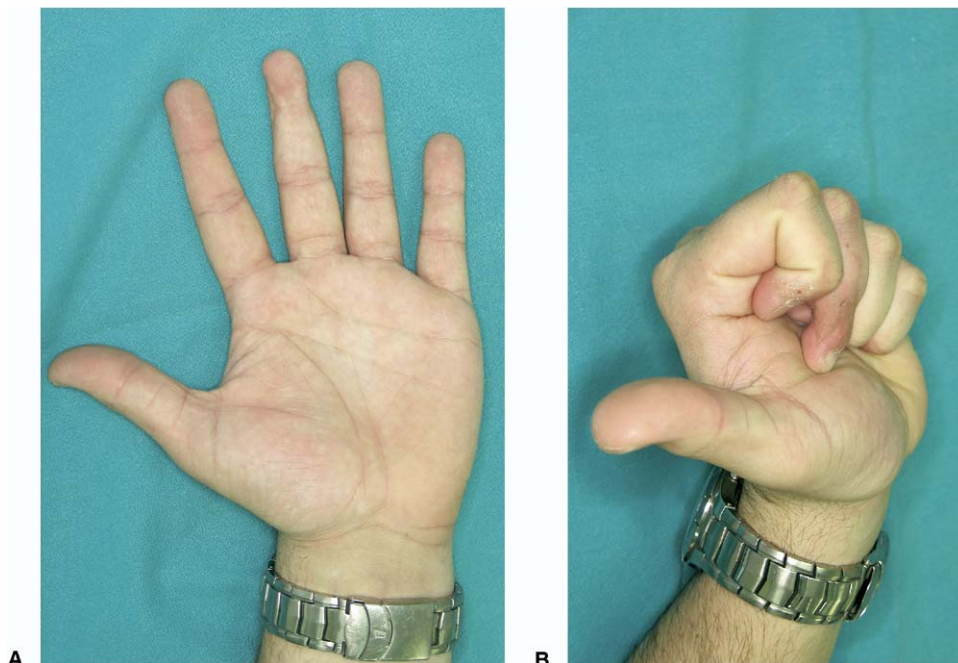


Figure 4. Functional result of the same patient shown in Figures 2 and 3 (patient 1). (A) Extension; (B) flexion.

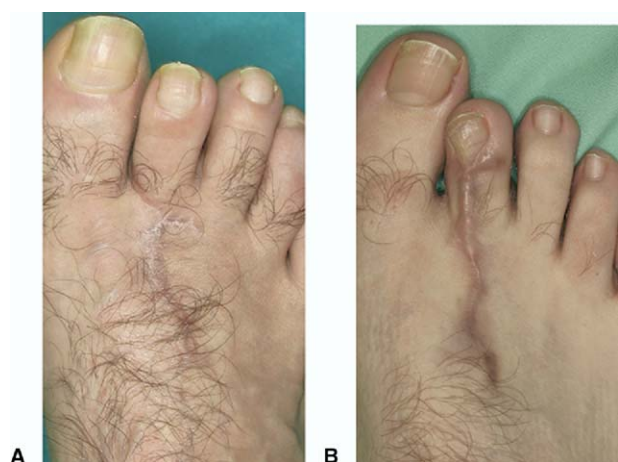

Figure 5. (A) Average and (B) worst donor site results (patients 3 and 4, respectively, at 1 year). Patient 4 still has some scar hypertrophy.

complaint from the donor site was reported by any patient. Patients rated the appearance of the donor site highly (Table 2). The American Orthopaedic Foot and Ankle Society questionnaire scores (maximum, 95) ranged from 85 to 95 (average, 93) (Fig. 5).

All patients were satisfied or very satisfied and would recommend the procedure to others. All returned to their preoperative occupation at an average of 93 days (range, 43–180 d). Patients 3 and 6 had concomitant damage to other parts of the hands.

Discussion

Bony defects are a common problem for the hand surgeon. Most can be dealt with by a nonvascularized bone graft.^{1–5,16,17}

When the defect to be reconstructed is located in a finger and there is the need for a vascularized bone graft for any reason, the problem is that there are virtually no donor sites. Cortical segments from long bones—namely the radius,²¹ humerus,²² ulna,^{23,24} and metatarsals^{25,26}—have been transferred successfully to the hand. With some exceptions most of the literature is composed of case reports. The lack of popularity of the use of vascularized bone graft, is partly because the smaller the bone graft to be harvested, the more difficult it is to include its feeding vessels, making these bony transfers inconsistent when a small defect needs to be reconstructed. Only small bone blocks from the iliac crest and the medial femoral condyle have been transferred to the hand reliably.^{14,15,27} Unfortunately the skin component of those 2 flaps is too bulky for a finger. Vascularized corticoperiosteal flaps have been suggested to avoid the problem of bulkiness and for better matching to

the upper-limb bone defect.^{7,28–31} Even these, however, are too large for a finger defect.

The distal radius is a source of small corticocancellous blocks. They have been used successfully to treat difficult nonunion of the scaphoid, Kienböck's disease, and even phalangeal defects.^{32–34} A small skin island can be included with the flap^{32,34} but the skin at the wrist level has a much larger subcutaneous panniculus than at the finger. Therefore this donor site also was disregarded.

Local flaps including bone from the head of the metacarpals have been used by several surgeons^{35–37} for finger reconstruction. Although they can carry skin they do not reach further distally than the proximal phalanx, and the amount of skin is limited.

The blood supply to the toe phalanges has been studied by several investigators. Few toe proximal phalanges and none of the middle phalanges have an identifiable nutrient artery.³⁸ The digital arteries, however, always provide tiny periosteal and capsular branches^{39–41} in a manner somewhat similar to the arterial distribution in the fingers.⁴² Two constant arcades encircle the neck of the proximal phalanx and the base of the middle phalanx^{39,40} whereas at the base of the proximal phalanx branches derived from the plantar and dorsal digital arteries have been identified going into the bone.^{39,40} These anatomic vascular studies and the long-term results on vascularized joint transfers^{43,44} support the reliability of this flap.

To decide which phalanx to harvest, in addition to the needs of the defect to be reconstructed (cartilage, skin) the length of bone required also should be taken into account: at times the middle phalanx is minute. We always take preoperative x-rays of the affected area, the contralateral healthy hand, and the toes in standing position (to measure their length). Then with tracing paper the defect is measured and transported to the foot to decide which phalanx to harvest.¹⁸ We have found the anatomic study by Gaul⁴⁵ on the shape of the toes' condyles extremely helpful in cases of defects around the PIP joint.

The middle phalanx is the preferred donor site because the pedicle will be longer. Before its take-off from the metatarsal arteries it is possible to dissect 3 to 4 cm of arterial pedicle. This usually is sufficient to perform the anastomosis to a digital artery away from the immediate area of injury. Conversely the proximal phalanx—particularly if the base is to be harvested (as in patients 2, 3, 6)—yields a much shorter pedicle (1–2 cm of proper digital artery) unless the dissection proceeds proximally on one of the metatarsal arteries. Inclusion of the parent meta-

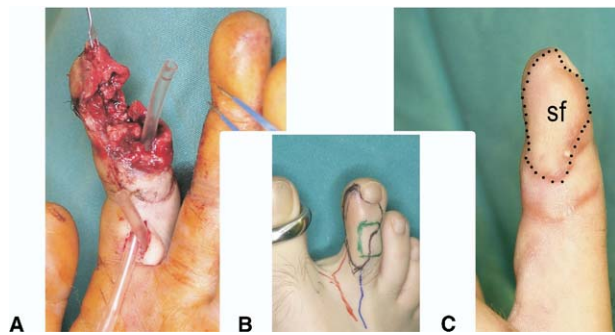


Figure 6. Patient 4. (A) After debridement. A compound defect on the ulnar side of the index finger 14 days after an open fracture–dislocation of the DIP joint resulted in infection and soft-tissue necrosis. The radial neurovascular bundle is intact. (B) Flap design. (C) Six months after the reconstruction. The donor site for this patient is shown in Figure 5B. sf, skin flap.

tarsal artery may not be beneficial because there could be major size discrepancies with the recipient digital artery. This discrepancy may be enhanced if the dorsal metatarsal artery is absent (Gilbert type III⁴⁶ [patient 6]) because in this case the first plantar metatarsal artery would be too large to match a proper digital artery of a finger.

Low et al⁴⁷ showed that vascularized bone grafts resist infection whereas similar nonvascularized segments suffer resorption when infected. An acutely infected case recurred 6 weeks after the surgery in the distal graft–distal phalanx interface, probably as a consequence of an inadequate debridement of the distal phalanx. The infection was controlled by debridement, cancellous bone grafting, and a 4-week course of intravenous antibiotics. The nonunion healed uneventfully, attesting to the robust blood supply of the transferred toe phalanx.

A theoretic problem of such small bone grafts may be insufficient outflow for the anastomosis, increasing the risk for thrombosis.⁴⁸ Neither our own experience on small free flaps taken from the toe nor long-term experience with vascularized joint transfers support these fears.^{18,43,44} Nevertheless we always include a piece of skin and a small cuff of soft tissues and this may increase the vascular bed sufficiently to maintain adequate outflow. We have insufficient data to support this policy but it seems reasonable not to skeletonize the artery or the vein in the very distal area, to avoid damaging the tiny branches going in and out from the bone.

The procedure has been safe in our experience, with no vascular crisis. The involved vessels, however, are rather small—in the supramicrosurgery range⁴⁹—and this type of surgery may be thought best reserved for busy microsurgical teams. Although

this may be true we should emphasize that the anastomosis is performed under ideal conditions—end-to-end, flat surface, and superficial location—as in a replant. Furthermore one may accept a failure because the alternative at times is amputation (Fig. 6). The loss in the event of failure is rather small (a deformity on the second toe). The benefit well may outweigh this risk.

Received for publication December 5, 2005; accepted in revised form March 21, 2006.

No benefits in any form have been received or will be received from a commercial party related directly or indirectly to the subject of this article.

Corresponding author: Francisco del Piñal, Dr Med, Calderón de la Barca 16-entlo, E-39002-Santander, Spain; e-mail: drpinal@drpinal.com, pacopinal@ono.com.

Copyright © 2006 by the American Society for Surgery of the Hand 0363-5023/06/31A07-0005\$32.00/0

doi:10.1016/j.jhsa.2006.03.021

References

- Berger A, Hernier R. Open metacarpal and phalangeal fractures. In: Brüser P, Gilbert A, eds. Finger bone and joint injuries. London: Martin Dunitz, 1999:89–93.
- Buchler U, Hastings H II. Combined injuries. In: Green DP, Hotchkiss RN, Pederson WC, eds. Green's operative hand surgery. Vol. 2. 4th ed. New York: Churchill Livingstone, 1999:1631–1650.
- Cziffer E, Farkas J, Turchanyi B. Management of potentially infected complex hand injuries. *J Hand Surg* 1991;16A:832–834.
- Freeland AE. Bone grafting. In: Freeland ME, ed. Hand fractures: repair, reconstruction and rehabilitation. New York: Churchill Livingstone, 2000:59–64.
- del Piñal Matorras F, Cruz Cámara A, Serrano Criado A, Herrero Fernández F. “Fijación interna mínima y espongioplastia inmediata” en fracturas abiertas conminutas del pulgar. *Cirugía Plástica Ibero-Latinoamericana* 1999;25:99–105.
- Taylor GI. The current status of free vascularized bone grafts. *Clin Plast Surg* 1983;10:185–209.
- Bishop AT. Vascularized bone grafting. In: Green DP, Hotchkiss RN, Pederson WC, Wolfe SW, eds. Green's operative hand surgery. 5th ed. Philadelphia: Elsevier, 2005:1777–1811.
- Gonzalez del Pino J, Bartolome del Valle E, Graña GL, Villanova JF. Free vascularized fibular grafts have a high union rate in atrophic nonunions. *Clin Orthop* 2004;419:38–45.
- Hausman MR, Rinker BD. Intractable wounds and infections: the role of impaired vascularity and advanced surgical methods for treatment. *Am J Surg* 2004;187:44S–55S.
- del Piñal F, García-Bernal JF, Delgado J, Regalado J, Sanmartín M. Reconstruction of the distal radius facet by a free vascularized osteochondral autograft: anatomic study and report of a case. *J Hand Surg* 2005;30A:1200–1210.
- Taylor GI, Miller GD, Ham FJ. The free vascularized bone graft. A clinical extension of microvascular techniques. *Plast Reconstr Surg* 1975;55:533–544.
- Taylor GI, Townsend P, Corlett R. Superiority of the deep

- circumflex iliac vessels as the supply for free groin flaps. *Clinical work. Plast Reconstr Surg* 1979;64:745–759.
13. Sekiguchi J, Kobayashi S, Ohmori K. Use of the osteocutaneous free scapular flap on the lower extremities. *Plast Reconstr Surg* 1993;91:103–112.
 14. Doi K, Oda T, Soo-Heong T, Nanda V. Free vascularized bone graft for nonunion of the scaphoid. *J Hand Surg* 2000;25A:507–519.
 15. Harpf C, Gabl M, Reinhart C, Schoeller T, Bodner G, Pechlaner S, et al. Small free vascularized iliac crest bone grafts in reconstruction of the scaphoid bone: a retrospective study in 60 cases. *Plast Reconstr Surg* 2001;108:664–674.
 16. Freeland AE, Jabaley ME. Stabilization of fractures in the hand and wrist with traumatic soft tissue and bone loss. *Hand Clin* 1988;4:425–436.
 17. Schecker LR, Langley SJ, Martin DL, Julliard KN. Primary extensor tendon reconstruction in dorsal hand defects requiring free flaps. *J Hand Surg* 1993;18B:568–575.
 18. del Piñal F. Invited personal view article. The indications for toe transfer after “minor” finger injuries. *J Hand Surg* 2004;29B:120–129.
 19. Buck-Gramcko D. The role of nonvascularized toe phalanx transplantation. *Hand Clin* 1990;6:643–659.
 20. Espinar Salom E. Sistemas de valoración de los resultados clínicos en la cirugía del pie. In: Núñez-Samper Pizarroso M, Llanos-Alcázar LF, Viladot Pericé R, eds. *Técnicas quirúrgicas de cirugía del pie*. Barcelona: Masson, 2003:361–370.
 21. Biemer E, Stock W. Total thumb reconstruction: a one-stage reconstruction using an osteo-cutaneous forearm flap. *Br J Plast Surg* 1983;36:52–55.
 22. Katsaros J, Schusterman M, Beppu M, Banis JC Jr, Acland RD. The lateral upper arm flap: anatomy and clinical applications. *Ann Plast Surg* 1984;12:489–500.
 23. Costa H, Smith R, McGrouther DA. Thumb reconstruction by the posterior interosseous osteocutaneous flap. *Br J Plast Surg* 1988;41:228–233.
 24. Akin S, Ozgenel Y, Ozcan M. Osteocutaneous posterior interosseous flap for reconstruction of the metacarpal bone and soft-tissue defects in the hand. *Plast Reconstr Surg* 2002;109:982–987.
 25. McFadden JA. Vascularized partial first metatarsal transfer for the treatment of phalangeal osteomyelitis. *J Reconstr Microsurg* 1998;14:309–312.
 26. Isenberg JS. Additional experience with hemi-metatarsal vascularized bone transfer for treatment of phalangeal osteomyelitis. *J Reconstr Microsurg* 2000;16:547–551.
 27. Grant I, Berger AC, Ireland DC. A vascularised bone graft from the medial femoral condyle for recurrent failed arthrodesis of the distal interphalangeal joint. *Br J Plast Surg* 2005;58:1011–1013.
 28. Sakai K, Doi K, Kawai S. Free vascularized thin corticoperiosteal graft. *Plast Reconstr Surg* 1991;87:290–298.
 29. Masquelet AC, Romaña MC. Vascularized periosteal flap. In: Wood MB, Gilbert A, eds. *Microvascular bone reconstruction*. London: Martin Dunitz, 1997:89–107.
 30. Beppu M. Vascularized thin corticoperiosteal graft from the medial femoral condyle. In: Tamai S, Usui M, Yoshizu T, eds. *Experimental and clinical reconstructive microsurgery*. Tokyo: Springer-Verlag, 2003:363–366.
 31. Fuchs B, Steinmann SP, Bishop AT. Free vascularized corticoperiosteal bone graft for the treatment of persistent nonunion of the clavicle. *J Shoulder Elbow Surg* 2005;14:264–268.
 32. Zaidenberg C, Siebert JW, Angrigiani C. A new vascularized bone graft for scaphoid nonunion. *J Hand Surg* 1991;16A:474–478.
 33. Moran SL, Cooney WP, Berger RA, Bishop AT, Shin AY. The use of the 4 + 5 extensor compartmental vascularized bone graft for the treatment of Kienbock’s disease. *J Hand Surg* 2005;30A:50–58.
 34. Dos Remedios C, Schoofs M. [The anterior interosseous flap in wrist and hand surgery: a series of fifteen cases.] *Chir Main* 2005;24:225–235.
 35. Pelissier P, Pistre V, Casoli V, Lim A, Martin D, Baudet J. Dorso-ulnar osteocutaneous reverse flow flap of the thumb. *J Hand Surg* 2001;26B:207–211.
 36. Santa-Comba A, Amarante J, Silva A, Rodrigues J. Reverse dorsal metacarpal osteocutaneous flap. *Br J Plast Surg* 1997;50:555–558.
 37. Cavadas PC. Reverse osteocutaneous dorsoulnar thumb flap. *Plast Reconstr Surg* 2003;111:326–329.
 38. Mysorekar VR, Nandedkar AN. Diaphysal nutrient foramina in human phalanges. *J Anat* 1979;128:315–322.
 39. Yoshizu T, Watanabe M, Tajima T. Étude expérimentale et applications cliniques des transferts libres d’articulation d’orteil avec anastomoses vasculaires. In: Tubiana R, ed. *Traité de chirurgie de la main*. Vol 2. Paris: Masson, 1984:539–551.
 40. Chen YG, Cook PA, McClinton MA, Espinosa RA, Wilgis EF. Microarterial anatomy of the lesser toe proximal interphalangeal joints. *J Hand Surg* 1998;23A:256–260.
 41. Chen IC, Tsai TM, Firrell JC. Single pedicle vascularized double joint transfer: anatomic study of two models. *Microsurgery* 1998;18:312–319.
 42. Strauch B, de Moura W. Arterial system of the fingers. *J Hand Surg* 1990;15A:148–154.
 43. Tsubokawa N, Yoshizu T, Maki Y. Long-term results of free vascularized second toe joint transfers to finger proximal interphalangeal joints. *J Hand Surg* 2003;28A:443–447.
 44. Dautel G, Gouzou S, Vialaneix J, Faivre S. PIP reconstruction with vascularized PIP joint from the second toe: minimizing the morbidity with the “dorsal approach and short-pedicle technique”. *Tech Hand Upper Extrem Surg* 2004;8:173–180.
 45. Gaul JS Jr. Articular fractures of the proximal interphalangeal joint with missing elements: repair with partial toe joint osteochondral autografts. *J Hand Surg* 1999;24A:78–85.
 46. Gilbert A. Composite tissue transfer from the foot: anatomic basis and surgical technique. In: Daniller AJ, Strauch B, eds. *Symposium on microsurgery*. St Louis: Mosby, 1976:230–242.
 47. Low CK, Pho RW, Kour AK, Satku K, Kumar VP. Infection of vascularized fibular grafts. *Clin Orthop* 1996;323:163–172.
 48. Taylor GI, Ham FJ. The free vascularized nerve graft. A further experimental and clinical application of microvascular techniques. *Plast Reconstr Surg* 1976;57:413–426.
 49. Koshima I, Inagawa K, Urushibara K, Moriguchi T. Paraumbilical perforator flap without deep inferior epigastric vessels. *Plast Reconstr Surg* 1998;102:1052–1057.