

Vascularized Graft From the Metatarsal Base for Reconstructing Major Osteochondral Distal Radius Defects

Francisco del Piñal, MD, PhD, Melissa Klausmeyer, MD, Eduardo Moraleda, MD, Guillermo H. de Piero, MD, Carlos Galindo, MD, Alexis Studer, MD, Luis Cerezal, MD

Purpose To present our experience of reconstructing distal radius articular defects with a vascularized osteochondral graft from the metatarsal base and to present the mid-term outcomes.

Methods Seven patients (average age, 36 y; range, 26–55 y) who had reconstruction of major defects of the articular surface of the radius are presented. In 5, the lunate facet and sigmoid notch were reconstructed; in 1, an isolated defect on the surface of the lunate facet was reconstructed; and in 1, the scaphoid facet was reconstructed. In 6, the base of the third metatarsal was transferred, and in 1, the base of the second was transferred.

Results All flaps survived without complications. At the latest follow-up (range, 20 mo to 8 y), the flexion-extension arc improved an average of 50°, and the pain on a visual analog scale decreased from 8 to 1 on average. Disabilities of the Arm, Shoulder, and Hand score improved from 54 to 11 on average. One patient did not improve. No major complaints related to the donor site were mentioned (average American Orthopedic Foot and Ankle Society score of 96/100).

Conclusions Our mid-term results are promising; however, the decision-making process and the operation are complex. The operation is not indicated when the carpals are devoid of cartilage or when the defect involves the whole radius surface. (*J Hand Surg* 2013;38A:1883–1895. Copyright © 2013 by the American Society for Surgery of the Hand. All rights reserved.)

Type of study/level of evidence Therapeutic IV.

Key words Arthroscopy, distal radius malunion, wrist osteoarthritis, wrist pain.

MALUNITED INTRA-ARTICULAR DISTAL radius fractures pose a reconstructive challenge. Early corrective osteotomy can be successful,^{1,2} but it is not indicated for malunions when

the radius articular surface is shattered or the cartilage is gone. This latter scenario has been frequently managed with partial arthrodesis (radiolunate or radio-scapholunate).^{3,4} Although these procedures are effective for controlling pain, wrist motion is substantially decreased. Furthermore, overloading of the adjacent midcarpal joint may occur, with resultant degenerative osteoarthritis^{5,6} necessitating total arthrodesis in up to 50% of the patients.⁷ Involvement of the sigmoid notch, which is unavoidable when the ulnar part of the lunate fossa is malunited, compounds the problem considerably; and an additional salvage procedure for the distal radioulnar joint is also needed.⁸

From the Instituto de Cirugía Plástica y de la Mano, Private Practice and Hospital Mutua Montañesa, Santander, Spain.

Received for publication March 15, 2013; accepted in revised form July 12, 2013.

No benefits in any form have been received or will be received related directly or indirectly to the subject of this article.

Corresponding author: Francisco del Piñal, MD, PhD, Paseo de Pereda 20-1, E- 39004-Santander, Spain; e-mail: drpinal@drpinal.com.

0363-5023/13/38A10-0001\$36.00/0
<http://dx.doi.org/10.1016/j.jhssa.2013.07.013>

The aim of this study was to present the technique of vascularized osteochondral graft from the base of the metatarsal to reconstruct the articular surface of the radius and to present the mid-term results in 7 patients. With this approach, patients with distal radius cartilage degeneration or a multifragmented articular surface have the option of reconstruction of the joint surface rather than having primary arthrodesis.

MATERIALS AND METHODS

Between 2003 and 2010, 7 patients had reconstruction of the articular surface of the distal radius with a vascularized osteochondral graft from the metatarsal base (Table 1). In 5, the lunate facet and sigmoid notch were reconstructed; in 1, an isolated defect on the lunate facet was reconstructed; and in 1, the scaphoid facet was reconstructed. In 6 patients, we used the base of the third metatarsal. In 1 patient, we used the base of the second metatarsal because the pedicle to the third was not considered to be robust and the sigmoid notch did not need to be reconstructed. The patients were followed for an average of 5 years (range, 20 mo to 8 y). The average age of the patient was 36 years (range, 26 to 55 y). At the most recent follow-up, the patients were evaluated clinically for range of motion, grip strength with a Jamar dynamometer (Jamar, Clifton, NJ), with an 11-point visual analog scale for pain (0–10), and with a Disabilities of the Arm, Shoulder, and Hand score. We also administered the American Orthopaedic Foot and Ankle Society questionnaire for lesser toes. All patients had x-rays at the latest follow-up.

Our institution does not require institutional review board approval; however, all patients were aware of the treatment aims and understood the risks and possible benefits. Furthermore, informed consent was obtained for this operation, as well as for osteotomy, arthroscopic resection arthroplasty, or arthrodesis, because the final decision could vary depending on the intraoperative findings.

Statistical analysis

Preoperative and postoperative data for wrist range of motion, grip strength, visual analog scale score, and Disabilities of the Arm, Shoulder, and Hand score were compared statistically using a 2-tailed, paired *t*-test.

Indications and contraindications

After a preoperative work-up, which included x-rays and computed tomography (CT) scan, a patient with a radius malunion is approached in the following

TABLE 1. Demographics

Case	Age	Sex	Follow-Up (y)	Dominance	Work	Delay (mo)	Initial Treatment	Additional Treatment (Before Referral)
1	33	M	8.5	ND	Painter	6	Volar plate	None
2	55	M	7.5	D	Mason	3	Volar locking plate/ulnar plate	None
3	33	M	7	D	Shelve stocker	17	Ext fix + K-wires	Radius osteotomy at 2 mo. with ext fix + screws
4	45	M	6	D	Truck driver	46	Ext fix	None
5	30	M	5.5	ND	Administrator	21	Ext fix + K-Wires	None
6	26	M	2	ND	Vertical mason (he climbs and repairs facades)	4	Volar locking plate + ext fix	None
7	31	F	1.5	D	Housewife	24	Volar plate and ulnar plate	4 previous surgeries; latest 6 months prior Reduction; osteotomy; osteotomy; hardware removal

D, dominant; ND, nondominant; ext fix, external fixator.

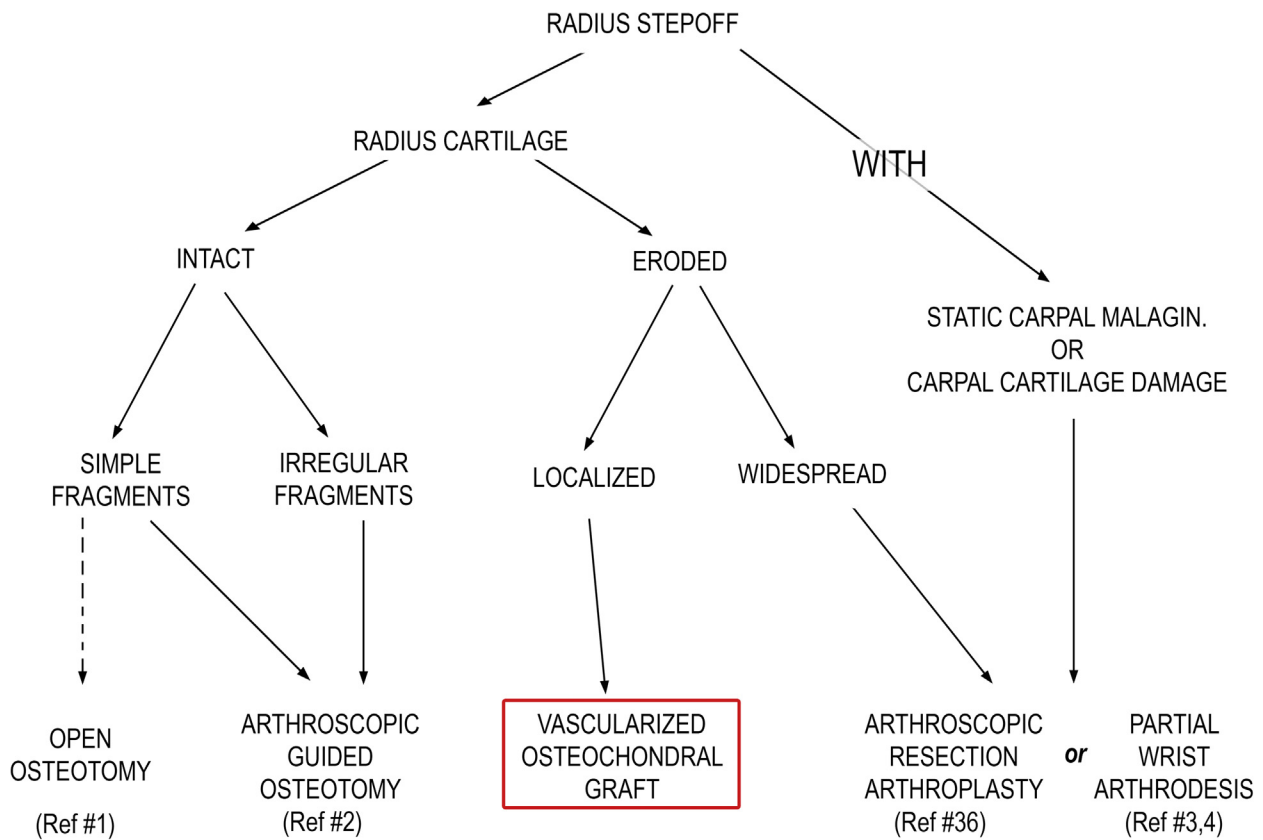


FIGURE 1: Flowchart used by the authors in the decision-making process of a stepoff in the distal radius.^{1-4,36} MALAGIN., malalignment.

manner (Fig. 1). First, arthroscopy is performed to evaluate the carpal cartilage. If there is cartilage loss of the carpal surfaces, a salvage procedure (ie, an arthrodesis or an arthroplasty) is performed. If it is spared, the radial cartilage is then evaluated. If corrective osteotomies are not feasible to restore the anatomy and the cartilage damage is limited to either the scaphoid or lunate facet, this index operation is performed. Its prime indication is when both the lunate facet and sigmoid notch are involved, because with a single flap, the radiocarpal and distal radio-ulnar relationships and functions are restored (Fig. 2).

Ideally, the carpal cartilage should be spared, but some allowances (fibrosis and scarred tissue rather than a healthy cartilage cover) can be made, particularly when the sigmoid notch will be reconstructed simultaneously. Frank cartilage loss of the carpal surfaces is a contraindication for the procedure. Due to size limitations (see next section),⁹ the base of the third metatarsal cannot replace both the scaphoid and lunate facet at the same time; therefore, if the whole radius surface is involved, the operation is contraindicated.

As is customary in our microsurgical practice, smoking habits were not considered a contraindication.

Only patients 5 and 7 had never smoked. Refraining from smoking is advised, although few did so except for the immediate perioperative period.

Donor site anatomy

In a previous anatomic study, the feasibility of reconstructing the distal radius facet with the base of the third metatarsal was analyzed.⁹ Briefly, the base of the third metatarsal has a principal facet that articulates with the third cuneiform and an accessory facet that articulates with the base of the fourth metatarsal (Fig. 3). The dimensions and shape of the former (19 mm length dorso-plantar, dorsal width 12 mm, and plantar width 8 mm) allowed replacing either the lunate or scaphoid facet.^{9,10} The accessory facet is 8 × 8 mm and located laterally, in the most dorsal aspect of the third metatarsal base. It is invaluable when the sigmoid notch also needs to be replaced. The principal articular surface of the second metatarsal base is not so similar to the distal radius articular surface as the base of the third. Furthermore, its accessory facet is irregular and unpredictable.

In all the specimens in the anatomical study,⁹ a periosteal artery could be traced to the dorsalis pedis

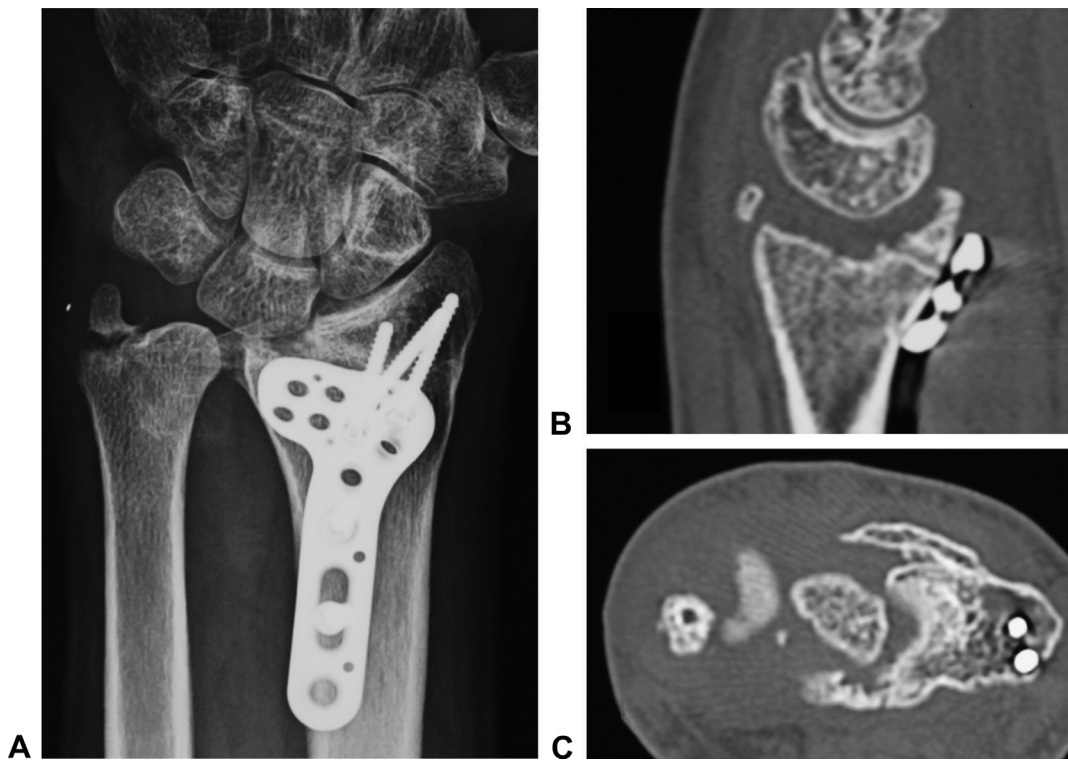


FIGURE 2: The ideal candidate for the index operation (patient 6): a massive osteochondral defect of 1 of the facets of the radius. The scaphoid fossa was not damaged. The sigmoid notch and lunate facet had cartilage damage, but the lunate and ulnar head cartilage were well preserved. **A** Preoperative radiographs. **B** Sagittal and **C** axial tomographic scan.

artery. In two-thirds of the specimens, the distal lateral artery was the dominant feeding vessel, whereas in a third of the specimens, the arcuate artery was the dominant vessel.

Preoperative planning

All patients had preoperative plain x-rays and CT scan. The CT scan is invaluable to evaluate the congruity of the rest of the joint, as widespread damage contraindicates this procedure. The CT scan also helps to define other fragments that may benefit from osteotomy and repositioning. For instance, if a dorsal segment is irreversibly damaged but is adjacent to a malunited but vascularized volar fragment, the volar fragments may be cut and reduced, and the vascularized metatarsal may be used to reconstruct the dorsal surface only. In this series, there were no cases of anterior fragment reconstruction or need to use a volar approach.

Surgical technique

The wrist was approached through a longitudinal, dorsal midline incision. The extensor pollicis longus was released from the third extensor compartment, and the second and fourth extensor compartments were elevated from the radius subperiosteally. The

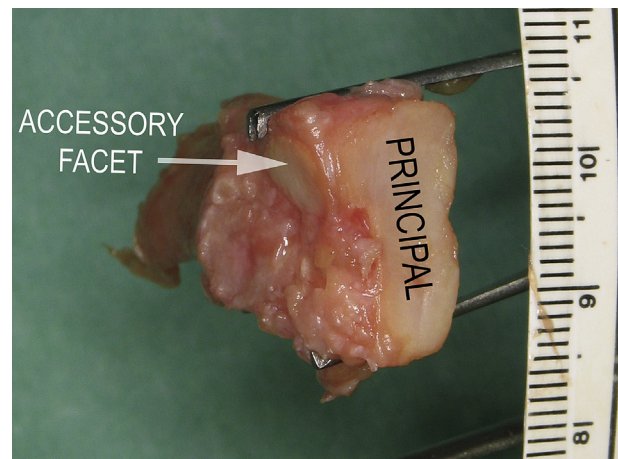


FIGURE 3: Left third metatarsal base, seen with proximal aspect in the foreground. Notice that the accessory facet is located dorsally and laterally.

posterior interosseous nerve was resected. The capsule was then dissected from the dorsal rim of the radius. The affected area of the distal radius was removed with an osteotome, sagittal saw, or rongeur. This excision included the metaphyseal bone to create a 3-dimensional defect to allow for placement of the osteochondral graft. Through the space created by the excision, the volar distal radius was accessed as

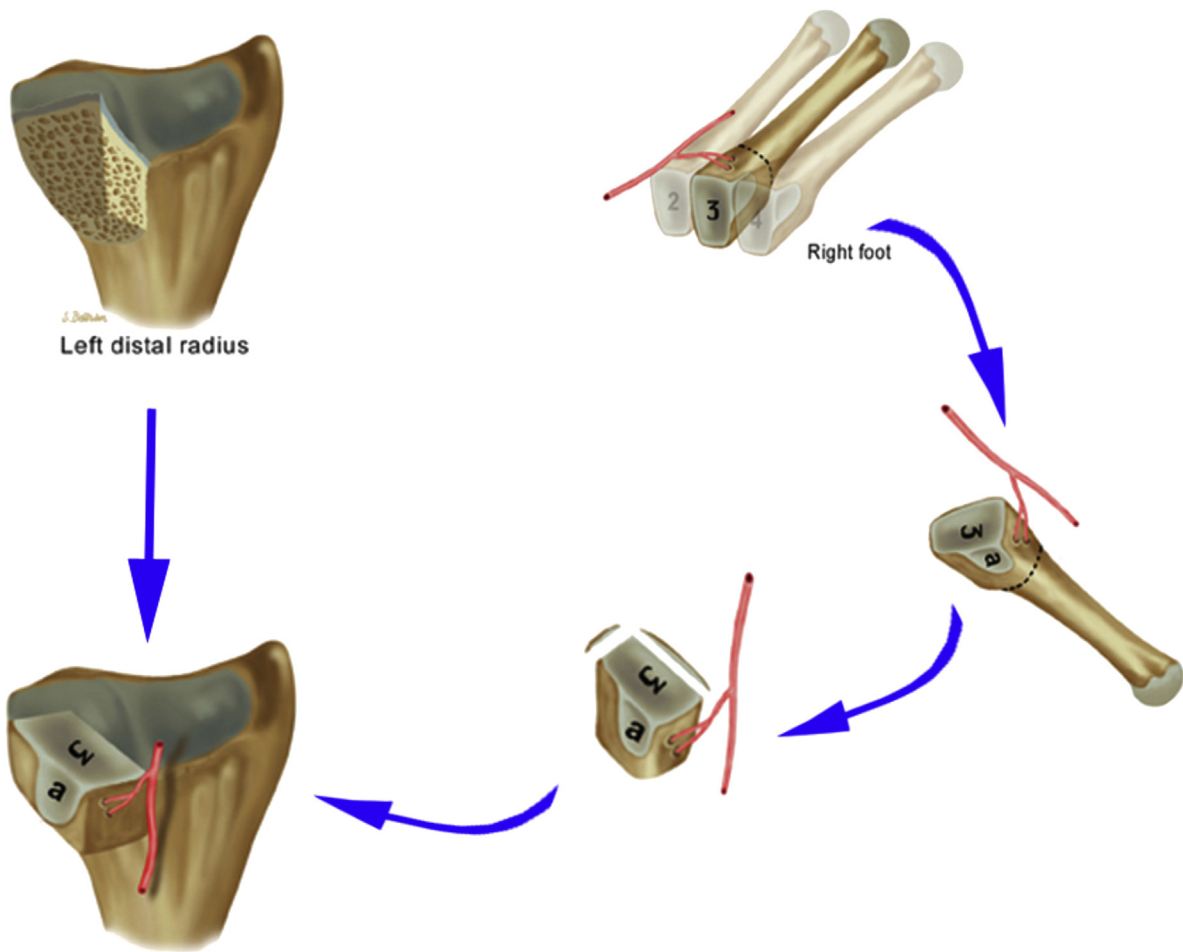


FIGURE 4: To reconstruct the typical dorsal-ulnar radius malunion scenario, when the defect involves not only the lunate facet but also the dorsal aspect of the sigmoid notch, the contralateral metatarsal must be harvested.

needed. Any malpositioned fragments with healthy cartilage were mobilized under visual control. K-wires were then used for fixation of these fragments to the radius metaphysis.

To reconstruct the scaphoid fossa, either third metatarsal can be harvested. To reconstruct the lunate fossa and sigmoid notch, the contralateral metatarsal must be harvested for the accessory facet to recreate the corresponding sigmoid notch in the wrist. The ipsilateral metatarsal will not match (Fig. 4).

To ensure that the blood supply to the foot will not be jeopardized after the operation, the presence of a posterior tibial artery was confirmed with a Doppler probe at the retromalleolar space while the surgeon occluded the dorsalis pedis artery. No other vascular study was performed because the caliber of the vessels supplying the base of the third metatarsal is too small to be detected. The lower extremity was exsanguinated by elevation (without compression) to allow for better visualization of the tiny periosteal vessels during dissection. A zigzag incision was

made between the extensor hallucis longus and the extensor digitorum longus. The extensor hallucis brevis tendon was divided and retracted laterally with the extensor digitorum longus. This maneuver exposed the vascularity of the bones of the dorsum of the foot (Fig. 5). One of the small perforators going to skin, emerging from the dorsalis pedis—first dorsal metatarsal vessels, was isolated and followed to the skin to be used as a monitor after surgery. The skin island was no more than 1 cm wide and was included in the transfer.

The feeding vessels were identified and protected by including a cuff of periosteum to prevent shearing the vessels off the bone. After the tissue was isolated on the dorsalis pedis artery, the third metatarsal was cut with an oscillating saw, about 1.5 cm distal to the cuneiform or distal to the arcuate artery, if present. The bone was then freed from its ligamentous attachments until it was pedicled on the nutrient vessels. The terminal branch of the deep peroneal nerve was severed only if it was interposed between the

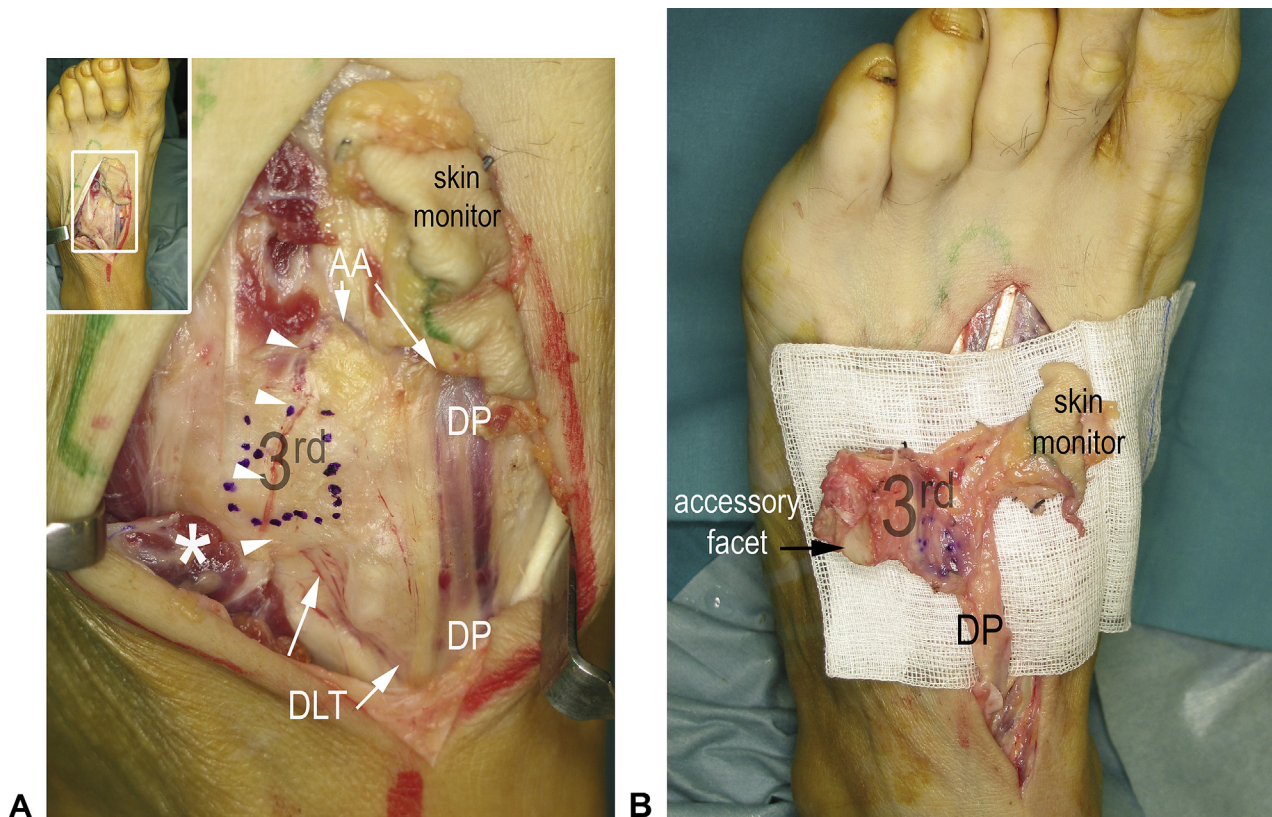


FIGURE 5: Flap elevation. **A** The extensor hallucis brevis has been divided and reflected laterally (asterisk), exposing the feeding vessels to the base of the third metatarsal (blue dots). Notice the connection (white arrowheads) between the distal lateral tarsal artery (DLTA) and the arcuate artery (AA; inset, panoramic view). **B** The flap is completely dissected on the dorsalis pedis vessels (DP).

different vessel branches. If it must be sacrificed as part of the dissection, it should be resected proximal to the annular ligament to prevent a painful postoperative neuroma.

The graft was then tailored to fit the distal radius defect. An estimate of the size of the graft could be calculated before surgery by the CT scan, but during surgery, several modifications and attempts were needed until the best fit was achieved. The corresponding medial or lateral cortex of the metatarsal was removed to appose the donor cancellous bone to the cancellous bone of the radius. The graft was secured with 2 lag screws. The dorsalis pedis artery was then anastomosed to the radial artery in an end-to-side fashion in the anatomical snuffbox, and the vein was connected to a vena concomitans or subcutaneous vein. The wrist was closed in a layered fashion and included the skin island as a monitor.

When concomitant osteotomies were performed, a neutralizing external fixator was applied and left in place for 4 to 5 weeks. In the others, a simple volar orthosis was applied. Active and active assisted exercises began after 5 weeks, with continued splint use for comfort between exercises for 2 to 4 more weeks.

Passive exercises were added at 8 weeks. After 10 to 12 weeks, strengthening exercises were added.

The foot incision was closed in layers over a suction drain. No attempt was made to reconstruct the metatarsal base. To control postoperative foot swelling, elevation and a compression stocking were recommended. Ambulation in a cast shoe was permitted starting on the first postoperative day, and the shoe was weaned after 4 to 6 weeks.

RESULTS

Intraoperative findings

In all cases, the dorsalis pedis artery was used as the pedicle. The dominant blood supply to the base of the third metatarsal was the arcuate artery in 3 cases and the distal lateral tarsal artery in 2. Both vessels were similar in size in another 2 cases. The vessels of the third metatarsal in patient 4 were considered insufficient to support the vascularized bone graft, so the base of the second metatarsal was harvested instead. Patient 5 had a hypoplastic anterior tibial-dorsalis pedis artery, but the blood supply to the base of the third metatarsal was unaffected, so the hypoplastic

dorsalis pedis artery was used as the feeding vessel (Table 2). The venous drainage was via the venae comitantes in all cases. No vascular complications occurred, and all flaps survived including the skin monitor.

Concomitant surgery to repair malunited fragments of the distal radius or ulnar surgery was performed as indicated (Table 2).

Follow-up findings

On average, extension improved $30^\circ \pm 10^\circ$ ($P = .016$), and flexion improved $20^\circ \pm 18^\circ$ ($P = .001$) (total postoperative flexion-extension arc of 100°). Pronation and supination were considered only for the patients who had a sigmoid notch reconstruction (patients 2, 3, 5, 6, and 7), and improved on average $21^\circ \pm 5^\circ$ ($P = .106$) and $42^\circ \pm 15^\circ$ ($P = .039$), respectively (total postoperative pronation-supination arc of 172°). Average grip strength improved from 45% of the contralateral hand before surgery to $86\% \pm 16\%$ after surgery ($P = .006$). The average visual analog scale pain score improved from 8 to 1 ± 3 ($P < .001$), and the average Disabilities of the Arm, Shoulder, and Hand score improved from 54 to 11 ± 12 ($P < .001$). (Detailed information on each patient is given in Tables 3 and 4).

Donor site pain was found in all patients and lasted for 2–3 months. Satisfaction was high at the last follow-up visit (average American Orthopedic Foot and Ankle Society score of 96/100). All patients resumed their previous work except patient 2 who retired as a consequence of concomitant vertebral and hip fractures. Patient 7 complained of continued pain at the radiocarpal joint and is waiting for a salvage procedure at this level. Her distal radioulnar joint pain has abated, however.

All patients had x-rays at their latest follow-up. No hardware loosening or signs of osteoarthritis (subchondral cysts, joint narrowing, sclerosis) were seen. The transferred metatarsal was visualized (as it is not a perfect replica of the radial defect) but did not show signs of resorption (Fig. 6). Postoperative x-rays of the foot showed recession of the metatarsal and the unfilled proximal defect.

Complications

In 2 patients (patients 3 and 7), replacement of most of the cartilage surface of the lunate by fibrotic, scarred tissue was noted during surgery. However, because both the lunate and sigmoid notch were involved, the surgery was not aborted. Patient 3 was very satisfied, has no pain, and returned to his high-demand work (Fig. 7). Patient 7 was unsatisfied

because she still had pain at the radiocarpal joint, although pain at the distal radioulnar joint had abated.

Further surgery was required in patient 4 because of persistent pain at the site of the ulnar styloid nonunion, which was not recognized as a source of pain before surgery. Excision of the styloid through a mini-ulnar approach abated his symptoms. Patient 1 requested the hardware to be removed. Patient 2 had the volar fracture fixation plate (unrelated to the procedure) removed. The skin island was excised concomitant to other procedures in 2 patients and exclusively for cosmetic reasons in 1 (Table 2).

Patient 1 had a neuroma on the deep peroneal nerve that was not bothersome at the latest follow-up visit. Nevertheless, pain could be elicited on deep palpation. Patient 5 initially complained of soreness on the dorsum of the foot while jogging. His pain improved spontaneously, and by the end of the first year he was running half-marathons without pain.

DISCUSSION

Historically, hyaline cartilage was thought to be strictly avascular and to receive its nutrition only from the synovial fluid.^{11,12} However, recent investigations suggest that the subchondral bone blood supply is an important source of nutrition, and the cartilage is not as independent of circulation as was once thought.^{13–15} Indeed, damage to the subchondral bone vascular network has been implicated in the progression of osteoarthritis,¹³ and contact with subchondral bone is necessary for survival of osteochondral grafts.^{14,15}

Nonvascularized osteochondral grafts have been used in hand surgery, particularly for small joint reconstruction.^{16–18} However, many authors report resorption, joint space narrowing, and avascular necrosis with this technique,^{19–23} particularly with larger grafts. Conversely, many authors report long-term results of vascularized osteochondral grafts with preservation of joint space and maintenance of joint architecture.^{24–27}

Options to reconstruct the distal radius defects are limited. The proximal fibula is often used for larger defects (ie, tumor reconstruction). Innocenti et al report good long-term results in pediatric patients in whom remodeling occurs.²⁸ However, other reports in adults are complicated by ulnar translocation,²⁹ wrist subluxation,^{30–32} and degenerative changes.³³ The fibula is not a suitable option for the smaller defect created by a distal radius fracture.

At the radiocarpal joint, our procedure compares favorably to the arthrodesis alternatives. In our series,

TABLE 2. Findings

Case	Fossa Reconstructed	Carpal Cartilage Status	Dominant Blood Supply of the Flap*		Flap Fixation	Concomitant Procedures	Subsequent Procedures
			DLTA	AA			
1	Scaphoid fossa	Normal	+	+++	2.7 lag screws + ext fix	Repositioning of the anterior third of the scaphoid fossa	Screw removal (8 mo)
2	Lunate fossa/sigmoid notch	Normal	++	+++	2.0 lag screws	Diaphyseal ulnar shortening	Volar locking plate and skin island removed (9 mo)
3	Lunate fossa/sigmoid notch	Widespread lunate scarring	+++	+	2.0 lag screws + ext fix	Removal of screws in the scapholunate ligament	None
4 [†]	Lunate fossa	Normal	+	+	2.0 lag screws + ext fix (plus K-wire for anterior fragment)	Repositioning of the anterior third of the lunate fossa	Resection ununited ulnar styloid + island excision (13 mo)
5	Lunate fossa/sigmoid notch	Focal damage	++	++	2.0 lag screws + ext fix (plus K-wire for anterior fragment)	Repositioning of the anterior third of the lunate fossa	Skin island removed (12 mo)
6	Lunate fossa/sigmoid notch	Normal	+	+++	2.0 lag screws	Ulnar styloid nonunion fixation	None
7	Lunate fossa/sigmoid notch	Widespread lunate scarring	++	++	2.0 lag screws	None	None [‡]

DLTA, distal lateral tarsal artery; AA, arcuate artery; ext fix, external fixator.

*The sizes of the vessels have been arbitrarily graded by the first author (F.d.P.) for comprehensiveness as large (+++), medium (++), and small (+).

[†]The base of the second metatarsal was used.

[‡]This patient is pending a radioscapolunate arthrodesis.

TABLE 3. Range of Motion and Grip Strength

Case	Flexion		Extension		Radial Deviation		Ulnar Deviation		Pronation		Supination		Grip Strength (% Contralateral Side)	
	Pre	Post	Pre	Post	Pre	Post	Pre	Post	Pre	Post	Pre	Post	Pre	Post
1	35	55	5	40	5	10	15	25	N/A	N/A	N/A	N/A	31	73
2	35	66	-5	64	0	5	15	35	80	85	-10	75	14	100
3	25	50	10	35	5	5	28	30	80	90	60	90	24	69
4	31	58	40	50	18	20	23	28	N/A	N/A	N/A	N/A	69	96
5	35	40	20	40	0	5	40	40	45	80	10	55	74	98
6	55	75	0	55	0	16	15	50	40	90	20	70	41	100
7	10	20	55	55	10	12	25	30	80	80	90	90	59	63
Average	32	52	18	48	5	10	23	34	65	86	34	76	45	86
SD	13	18	22	10	7	6	9	9	21	5	40	15	23	16
P Value	.001		.016		.045		.058		.106		.039		.006	

Pre, preoperative; Post, postoperative; N/A, pronation-supination was unrelated to the procedure and, therefore, not included

TABLE 4. Results

Case	Follow-Up (y)	VAS		DASH		AOFAS
		Pre	Post	Pre	Post	
1	8.5	8	2	44	8	90
2	7.5	9	1	89	14	100
3	7	9	0	35	3	100
4	6	8	0	54	12	100
5	5.5	7	0	45	4	100
6	2	8	0	53	0	100
7	1.5	10	7	56	35	80
Average	5	8	1	54	11	96
SD		1	3	17	12	
<i>P</i> Value		<. 001		<. 001		

VAS, visual analog scale; DASH, Disabilities of the Arm, Shoulder, and Hand; AOFAS, American Orthopedic Foot and Ankle Society; Pre, pre-operative; Post, postoperative.

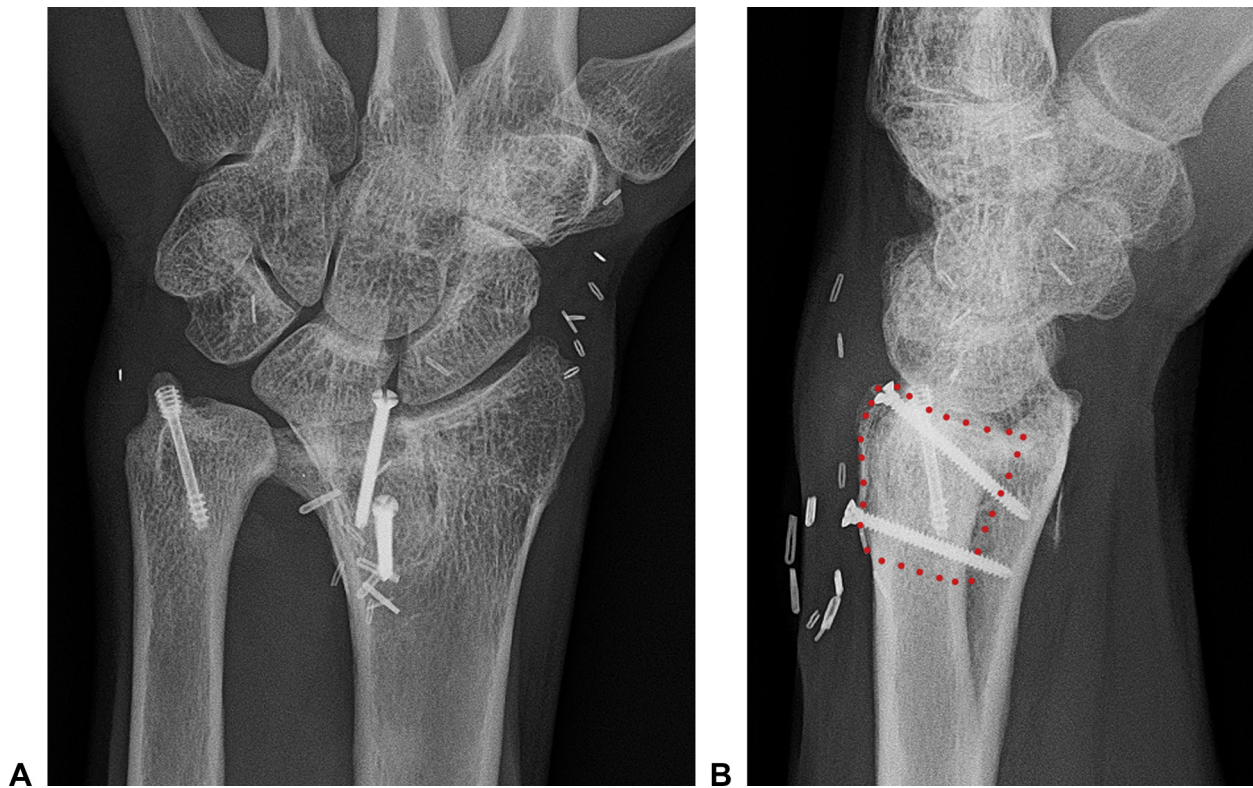


FIGURE 6: A, B Posteroanterior and lateral x-rays at 2 years, in the same patient (patient 6) as Figures 2 and 5.

we obtained a flexion-extension arc of 100° versus 66° in radiolunate⁴ and 67° in radioscapolunate arthrodeses.^{3,5} Preservation of motion at the radiocarpal joint prevents abnormal kinematics at the midcarpal joint and the subsequent risk of developing midcarpal arthritis.^{3,5,7} At the distal radioulnar joint, there are no alternatives to the index procedure when the

malpositioned radius fragments cannot be realigned³⁴ or when they are degenerated. None of the salvage operations (Darrach, Bowers, or prostheses) provide a close to normal range of motion or pain free pronation-supination.⁸

The procedure has several limitations and drawbacks. First, harvesting of the graft is difficult, even

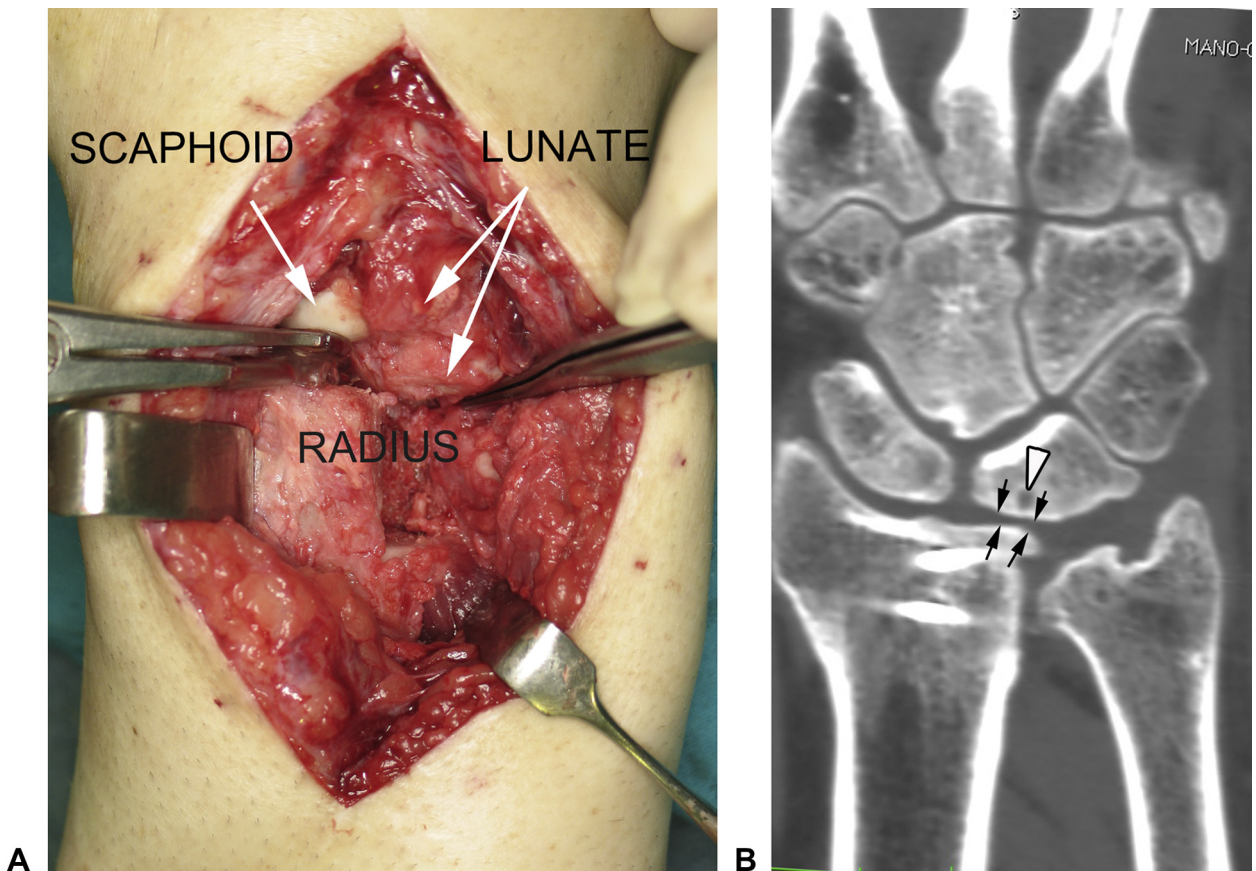


FIGURE 7: A, B Patient 3: **A** The cartilage on the proximal lunate has been replaced by scar tissue (compared to the healthy scaphoid cartilage). **B** Despite this, an acceptable result was obtained despite some narrowing (black arrows) and cysts (white arrowhead) evident on the 7-year follow-up CT scan.

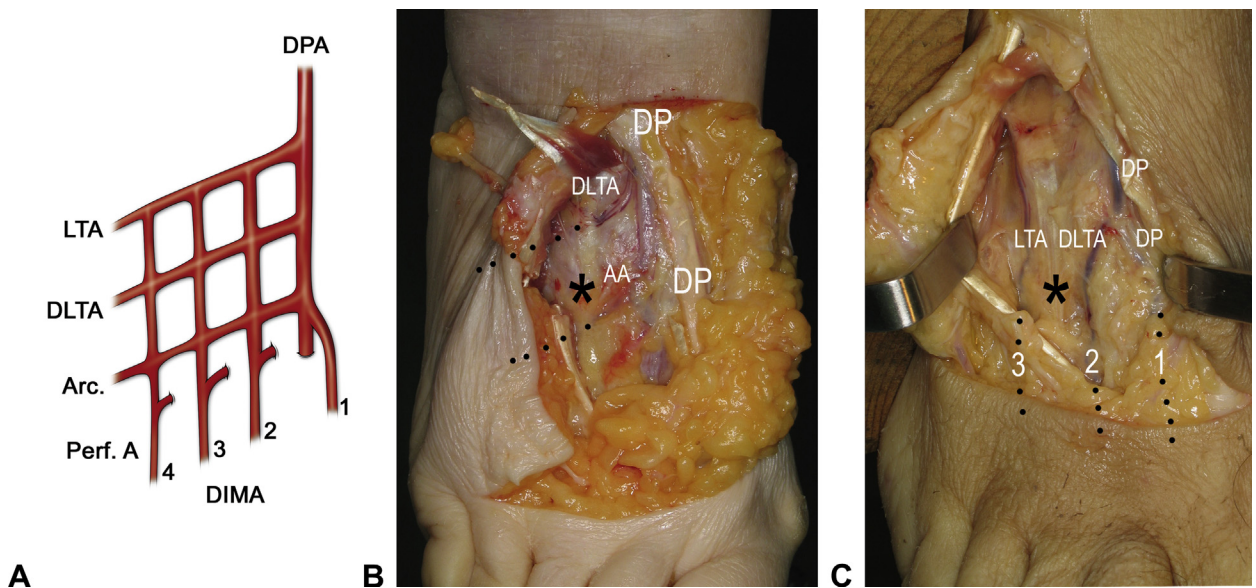


FIGURE 8: A The competitive nature of the blood supply of the dorsum of the foot is represented schematically. In a cadaver, the 2 extremes of this variability are highlighted. **B** Transverse vessels dominant. **C** Longitudinal vessels dominant. The asterisk marks the base of the third metatarsal. AA, arcuate artery; LTA, lateral tarsal artery; DLTA, distal lateral tarsal artery; DP, dorsalis pedis vessels; DPA, dorsalis pedis artery; Arc, arcuate artery; DIMA, dorsal intermetatarsal arteries; Perf. A., proximal.

for surgeons with ample microsurgical experience because of the great variability of the arterial network on the foot. Indeed, the classic anatomic description of the 3 lateral branches of the dorsalis pedis artery (proximal lateral tarsal, distal lateral tarsal, and arcuate arteries) is rare. Cormack and Lamberty's description³⁵ of a plexus of transverse and longitudinal vessels that communicate with the intermetatarsal arteries and that develop in a competitive fashion was consistent with the findings in our anatomical study (Fig. 8). In our experience, the metatarsal was supplied by the distal lateral tarsal artery, the arcuate artery, or both; however, in patient 4, the arteries were quite small, and the third metatarsal was not used. The shape of the second metatarsal did not restore the distal radius surface well, and there was no accessory facet for the sigmoid notch (confirming our anatomical studies).⁹ In this case, the sigmoid notch did not need to be reconstructed. In retrospect, the decision was taken too lightly, and the base of the third metatarsal should have been harvested. In addition to the difficulty of the harvest, fitting the graft in position is not easy and requires several trials before the anatomy is reasonably restored.

Another limitation of this study was the lack of long-term results. Radiocarpal degeneration may appear in the future despite the reconstruction. Nevertheless, this operation will not preclude any other salvage procedure if needed at a later date.

REFERENCES

1. Ring D, Prommersberger KJ, González del Pino J, et al. Corrective osteotomy for intra-articular malunion of the distal part of the radius. *J Bone Joint Surg Am.* 2005;87(7):1503–1509.
2. del Piñal F, Cagigal L, García-Bernal FJ, et al. Arthroscopically guided osteotomy for management of intra-articular distal radius malunions. *J Hand Surg Am.* 2010;35(3):392–397.
3. Garcia-Elias M, Lluch A, Ferreres A, et al. Treatment of radiocarpal degenerative osteoarthritis by radioscapulohumeral arthrodesis and distal scaphoidectomy. *J Hand Surg Am.* 2005;30(1):8–15.
4. Saffar P. Radio-lunate arthrodesis for distal radial intraarticular malunion. *J Hand Surg Br.* 1996;21(1):14–20.
5. Nagy L, Büchler U. Long-term results of radioscapulohumeral fusion following fractures of the distal radius. *J Hand Surg Br.* 1997;22(6):705–710.
6. Murray PM. Radioscapulohumeral arthrodesis. *Hand Clin.* 2005;21(4):561–566.
7. Mühlendorfer-Fodor M, Ha HP, Hohendorff B, et al. Results after radioscapulohumeral arthrodesis with or without resection of the distal scaphoid pole. *J Hand Surg Am.* 2012;37(11):2233–2239.
8. Coulet B, Onzaga D, Perrotto C, et al. Distal radioulnar joint reconstruction after fracture of the distal radius. *J Hand Surg Am.* 2010;35(10):1681–1684.
9. del Piñal F, García-Bernal FJ, Delgado J, et al. Reconstruction of the distal radius facet by a free vascularized osteochondral autograft: anatomic study and report of a patient. *J Hand Surg Am.* 2005;30(6):1200–1210.
10. Mekhail AO, Ebraheim NA, McCreath WA, et al. Anatomic and x-ray film studies of the distal articular surface of the radius. *J Hand Surg Am.* 1996;21(4):567–573.
11. Poole AR. What type of cartilage repair are we attempting to attain? *J Bone Joint Surg Am.* 2003;85(Suppl 2):40–44.
12. Wang Y, Wei L, Zeng L, et al. Nutrition and degeneration of articular cartilage. *Knee Surg Sports Traumatol Arthrosc.* 2012 Apr 4 Epub.
13. Imhof H, Sulzbacher I, Gramp S, et al. Subchondral bone and cartilage disease: a rediscovered functional unit. *Invest Radiol.* 2000;35(10):581–588.
14. Kock NB, Hannink G, van Kampen A, et al. Evaluation of subsidence, chondrocyte survival and graft incorporation following autologous osteochondral transplantation. *Knee Surg Sports Traumatol Arthrosc.* 2011;19(11):1962–1970.
15. Malinin T, Ouellette EA. Articular cartilage nutrition is mediated by subchondral bone: a long-term autograft study in baboons. *Osteoarthritis Cartilage.* 2000;8(6):483–491.
16. Calfee RP, Kiefhaber TR, Sommerkamp TG, et al. Hemi-hamate arthroplasty provides functional reconstruction of acute and chronic proximal interphalangeal fracture-dislocations. *J Hand Surg Am.* 2009;34(7):1232–1241.
17. Williams RM, Kiefhaber TR, Sommerkamp TG, et al. Treatment of unstable dorsal proximal interphalangeal fracture/dislocations using a hemi-hamate autograft. *J Hand Surg Am.* 2003;28(5):856–865.
18. Sato K, Sasaki T, Nakamura T, et al. Clinical outcome and histologic findings of costal osteochondral grafts for cartilage defects in finger joints. *J Hand Surg Am.* 2008;33(4):511–515.
19. Ishida O, Ikuta Y, Kuroki H. Ipsilateral osteochondral grafting for finger joint repair. *J Hand Surg Am.* 1994;19(3):372–377.
20. Boulas HJ, Herren A, Büchler U. Osteochondral metatarsophalangeal autografts for traumatic articular metacarpophalangeal defects: a preliminary report. *J Hand Surg Am.* 1993;18(6):1086–1092.
21. Tibesku CO, Szuwart T, Kleffner TO, et al. Hyaline cartilage degenerates after autologous osteochondral transplantation. *J Orthop Res.* 2004;22(6):1210–1204.
22. Gaul JS Jr. Articular fractures of the proximal interphalangeal joint with missing elements: repair with partial toe joint osteochondral autografts. *J Hand Surg Am.* 1999;24(1):78–85.
23. Foucher G, Hoang P, Citron N, et al. Joint reconstruction following trauma: comparison of microsurgical transfer and conventional methods: a report of 61 cases. *J Hand Surg Br.* 1986;11(3):388–393.
24. Foucher G, Lenoble E, Smith D. Free and island vascularized joint transfer for proximal interphalangeal reconstruction: a series of 27 cases. *J Hand Surg Am.* 1994;19(1):8–16.
25. Chen SH, Wei FC, Chen HC, et al. Vascularized toe joint transfer to the hand. *Plast Reconstr Surg.* 1996;98(7):1275–1284.
26. Hierner R, Berger AK. Long-term results after vascularised joint transfer for finger joint reconstruction. *J Plast Reconstr Aesthet Surg.* 2008;61(11):1338–1346.
27. Tsubokawa N, Yoshizu T, Maki Y. Long-term results of free vascularized second toe joint transfers to finger proximal interphalangeal joints. *J Hand Surg Am.* 2003;28(3):443–447.
28. Innocenti M, Delcroix L, Manfrini M, et al. Vascularized proximal fibular epiphyseal transfer for distal radial reconstruction. *J Bone Joint Surg Am.* 2004;86(7):1504–1511.
29. Van Demark RE Jr, Van Demark RE Sr. Nonvascularized fibular autograft to treat recurrent giant cell tumor of the distal radius. *J Hand Surg Am.* 1988;13(5):671–675.
30. Ferracini R, Gino G, Battiston B, et al. Assessment of vascularized fibular graft one year after reconstruction of the wrist after excision of a giant-cell tumor. *J Hand Surg Br.* 1999;24(4):497–500.
31. Saini R, Bali K, Bachhal V, et al. *En bloc* excision and autogenous fibular reconstruction for aggressive giant cell tumor of distal radius:

- a report of 12 cases and review of literature. *J Orthop Surg Res.* 2011;8:6–14.
32. Minami A, Kato H, Iwasaki N. Vascularized fibular graft after excision of giant-cell tumor of the distal radius: wrist arthroplasty versus partial wrist arthrodesis. *Plast Reconstr Surg.* 2002;110(1):112–117.
 33. Ono H, Yajima H, Mizumoto S, et al. Vascularized fibular graft for reconstruction of the wrist after excision of giant cell tumor. *Plast Reconstr Surg.* 1997;99(4):1086–1093.
 34. del Piñal F, Studer A, Thams C, et al. Sigmoid notch reconstruction and limited carpal arthrodesis for a severely comminuted distal radius malunion: case report. *J Hand Surg Am.* 2012;37(3):481–485.
 35. Cormack GC, Lamberty BG. Lower leg. In: Cormack GC, Lamberty BGH, eds. *The Arterial Anatomy of Skin Flaps.* 2nd ed. Edinburgh: Churchill Livingstone; 1994:248–267.
 36. del Piñal F, Klausmeyer M, Thams C, et al. Arthroscopic resection arthroplasty for malunited intra-articular distal radius fractures. *J Hand Surg Am.* 2012;37(12):2447–2455.